



CONVERTING **LIGHT**
INTO **VISION** AGAIN

KOL EVENT MEETING


An update on promising results with PRIMA in
advanced dry-AMD

MARCH 5, 2018



Forward Looking Statements

This document contains information on Pixium Vision's markets and competitive position, and more specifically, on the size of its markets. This information has been drawn from various sources or from the companies own estimates. Investors should not base their investment decision on this information. This document also contains certain forward-looking statements. These statements are not guarantees of the Company's future performance. These forward-looking statements relate to the Company's future prospects, developments and marketing strategy and are based on analyses of earnings forecasts and estimates of amounts not yet determinable. Forward-looking statements are subject to a variety of risks and uncertainties as they relate to future events and are dependent on circumstances that may or may not materialize in the future. Pixium Vision draws your attention to the fact that as forward-looking statements cannot under any circumstance be construed as a guarantee of the Company's future performance and that the Company's actual financial position, results and cash flow, as well as the trends in the sector in which the Company operate may differ materially from those proposed or reflected in the forward-looking statements contained in this document. Furthermore, even if Pixium Vision's financial position, results, cash-flows and developments in the sector in which the Company operates were to conform to the forward-looking statements contained in this document, such results or developments cannot be construed as a reliable indication of the Company's future results or developments. The Company does not undertake any obligation to update or to confirm projections or estimates made by analysts or to make public any correction to any prospective information in order to reflect an event or circumstance that may occur after the date of this presentation. A description of those events that may have a material adverse effect on the business, financial position or results of Pixium Vision, or on its ability to meet its targets, appears in the sections "Risk Factors" of its "Document de Base" filed with the French Autorité des Marchés Financiers. By attending this presentation or accepting this document, you agree to be bound by the foregoing restrictions set out above.



- A **Bioelectronics** company developing bionic vision systems to compensate for severe vision loss or **blindness**
- **PRIMA**, **miniaturized wireless** implant, **novel breakthrough** technology to treating blindness
- In **clinical stage** initially treating **dry age-related macular degeneration** (dry-AMD), a significant **unmet medical need**

Agenda

- 8:30 Welcome & introduction
K. Ishaque, CEO Pixium Vision
- 8:35 PRIMA inventor's motivation
Pr. D. Palanker
- 8:50 First in human study PRIMA in AMD
Pr. J-A. Sahel
- 9:05 Real world unmet medical need: Atrophic dry-AMD
Pr. F. Holz
- 9:20 Q&A
- 10:00 Close

PRIMA inventor's motivation

Daniel Palanker, PhD

Professor Department of Ophthalmology, School of Medicine,
and Director Hansen Experimental Physics Laboratory,
Stanford University, California, USA

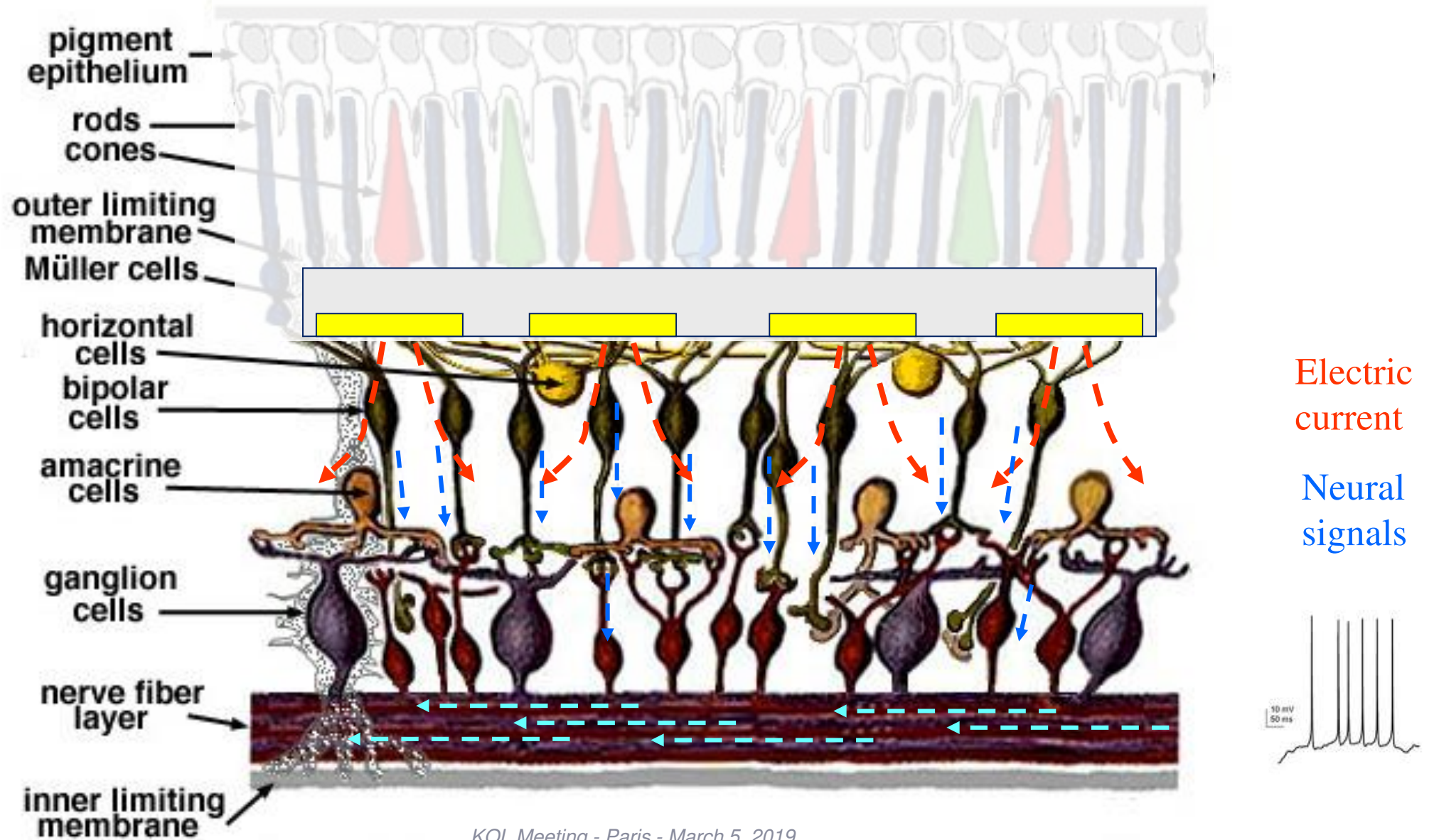
Photovoltaic Restoration of Sight in Age-Related Macular Degeneration

Daniel Palanker

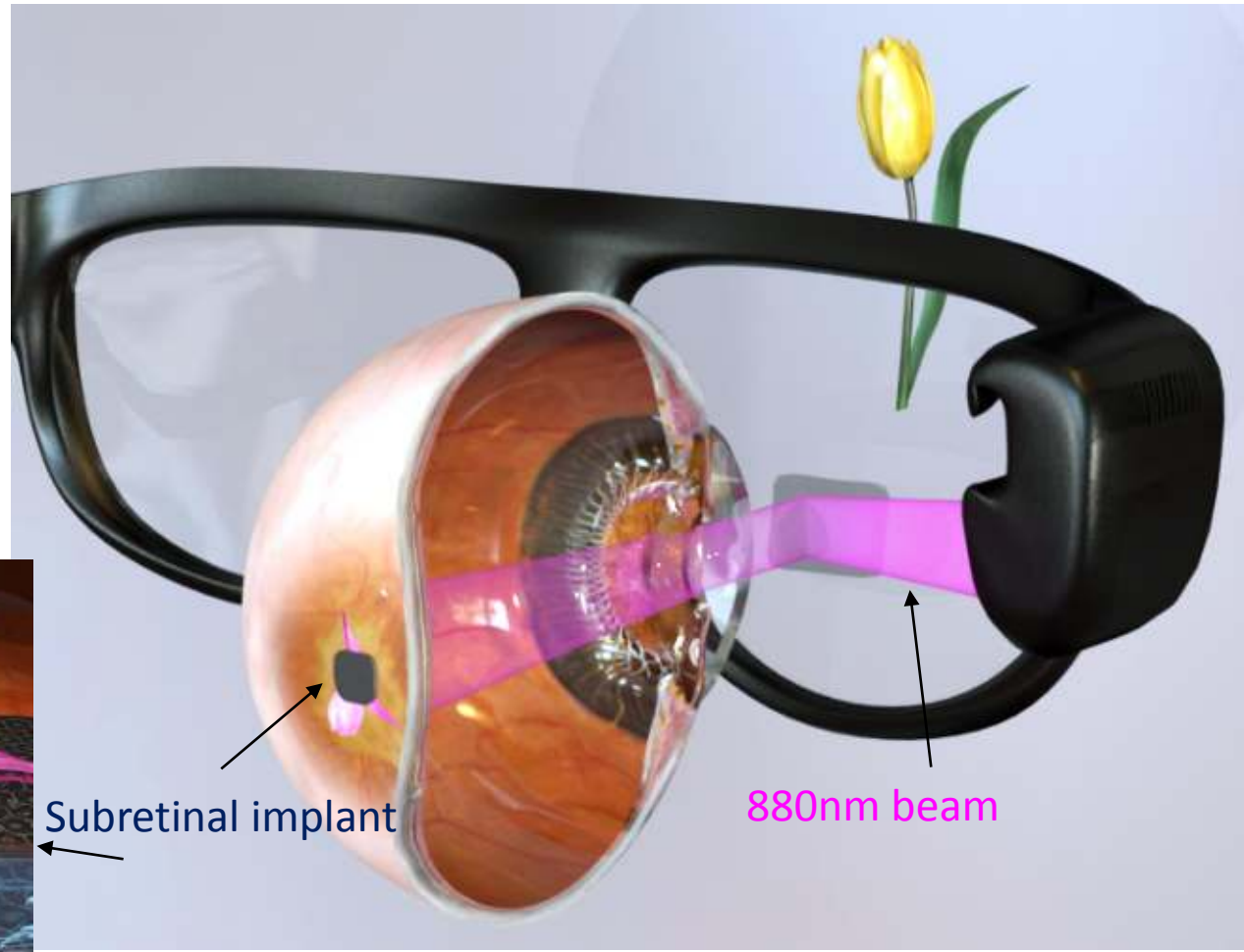

*Department of Ophthalmology and
Hansen Experimental Physics Laboratory
Stanford University, CA*



Subretinal Electrical Stimulation of the Bipolar Cells



Photovoltaic Retinal Prosthesis: System Design



20 μm pixels,
8 levels of grey

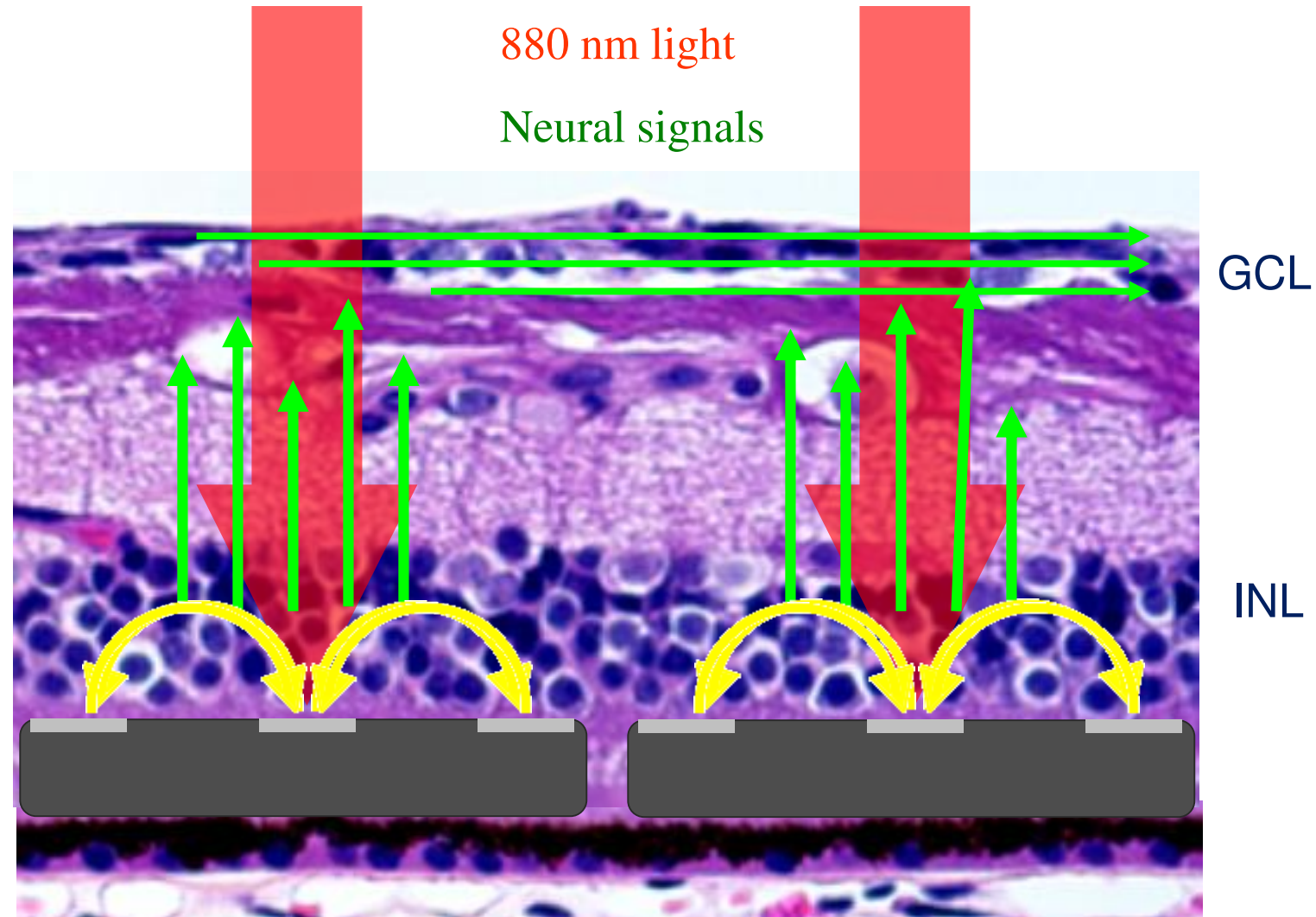


40

Operation of Subretinal Photovoltaic Prosthesis

Advantages of the photovoltaic approach:

- Simplicity of the PV implant allows its miniaturization and wireless operation.
- Small size and lack of wires enables minimally invasive surgery.
- Modular design enables enlarging visual field via small retinotomy.
- Image projection is naturally linked to eye movements.
- System enables image processing (autofocus, zoom, contrast enhancement, background removal, etc.).
- System can be integrated with advanced computer vision for naming the people, reading the text and other advanced functions.
- Image can be transferred directly from a computer to the video glasses for reading, watching TV, etc.

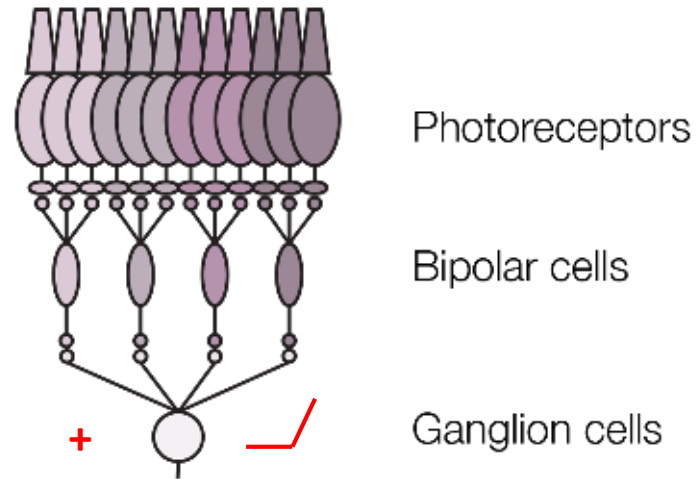


Photovoltaic Retinal Prosthesis: System Design

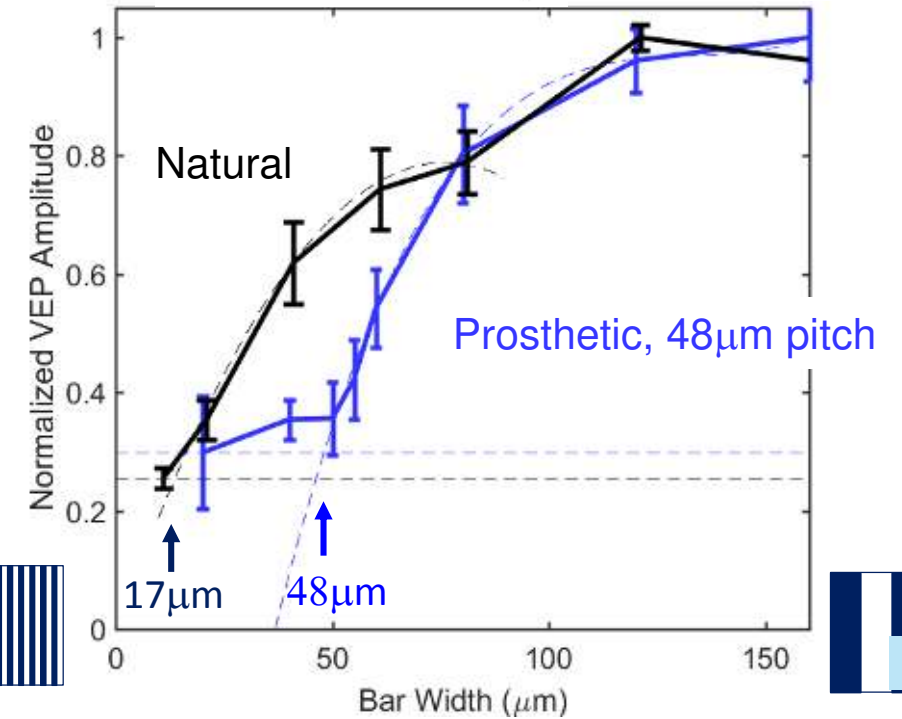
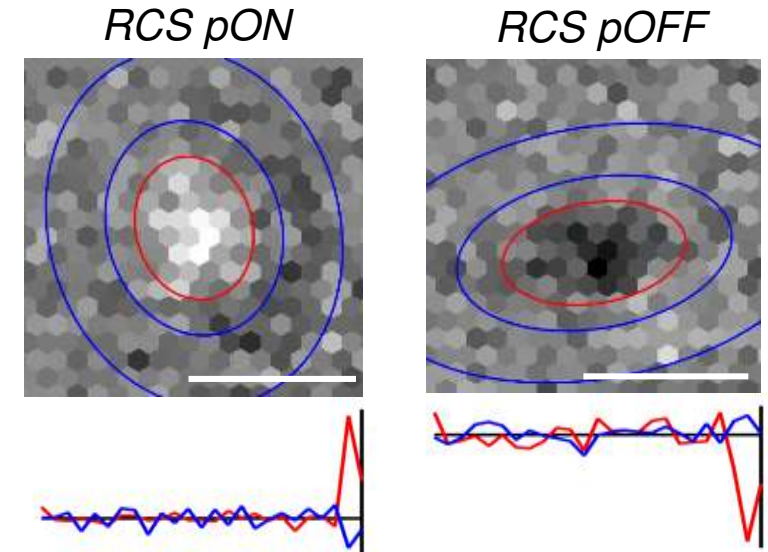


Benefits of the network-mediated retinal stimulation

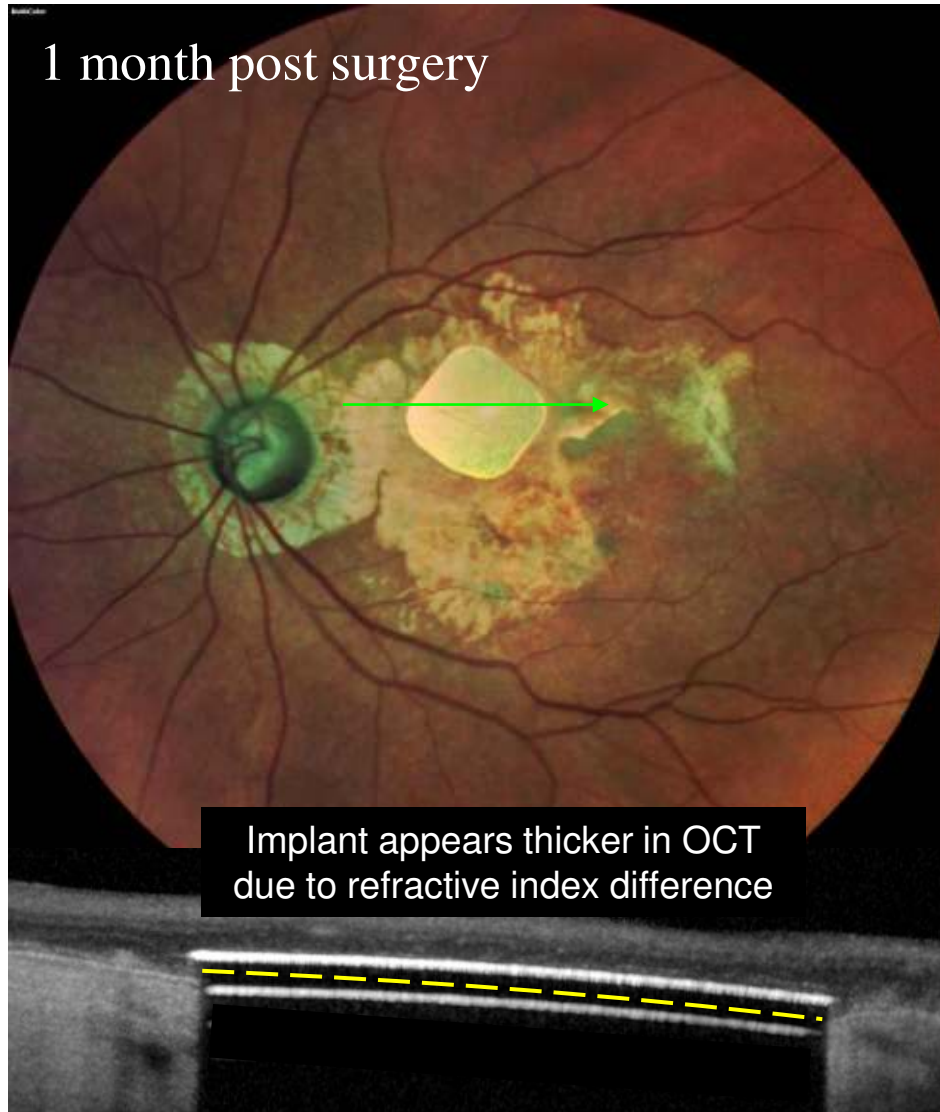
- Flicker fusion at high (>20Hz) frequencies (now confirmed in patients).
- Adaptation to static images.
- Antagonistic center-surround organization of receptive fields.
- ON and OFF responses.
- Linear and non-linear summation of subunits in RGC receptive fields, which is essential for high acuity.




- Spatial resolution matching the pixel pitch, at least up to 50 μm (equivalent of 20/200 acuity in a human eye).



Pilot clinical trial of the PRIMA system in patients with geographic atrophy



2x2 mm array, 30 μm thick, 100 μm pixels



All patients perceive bright white-yellow patterns of retinotopically correct shapes and locations.

Tests of Prosthetic Vision

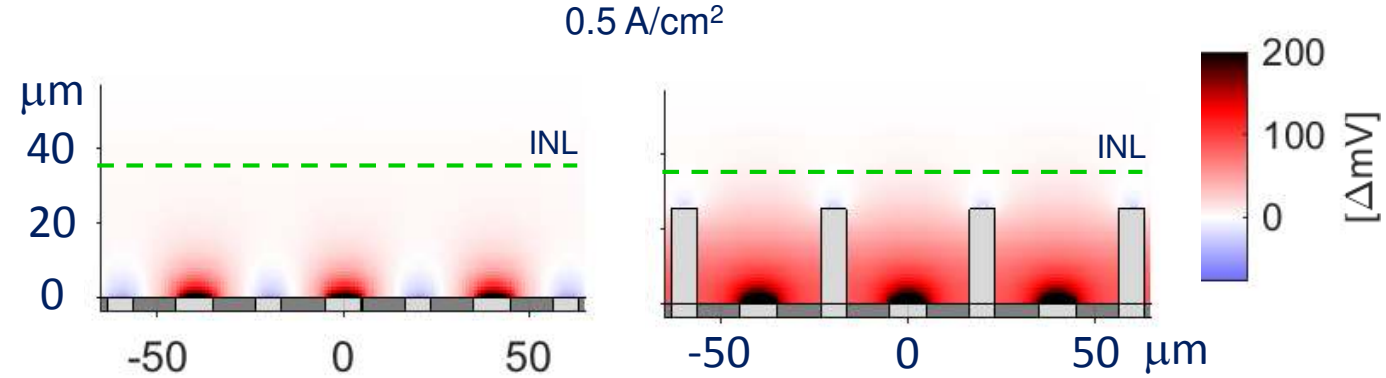
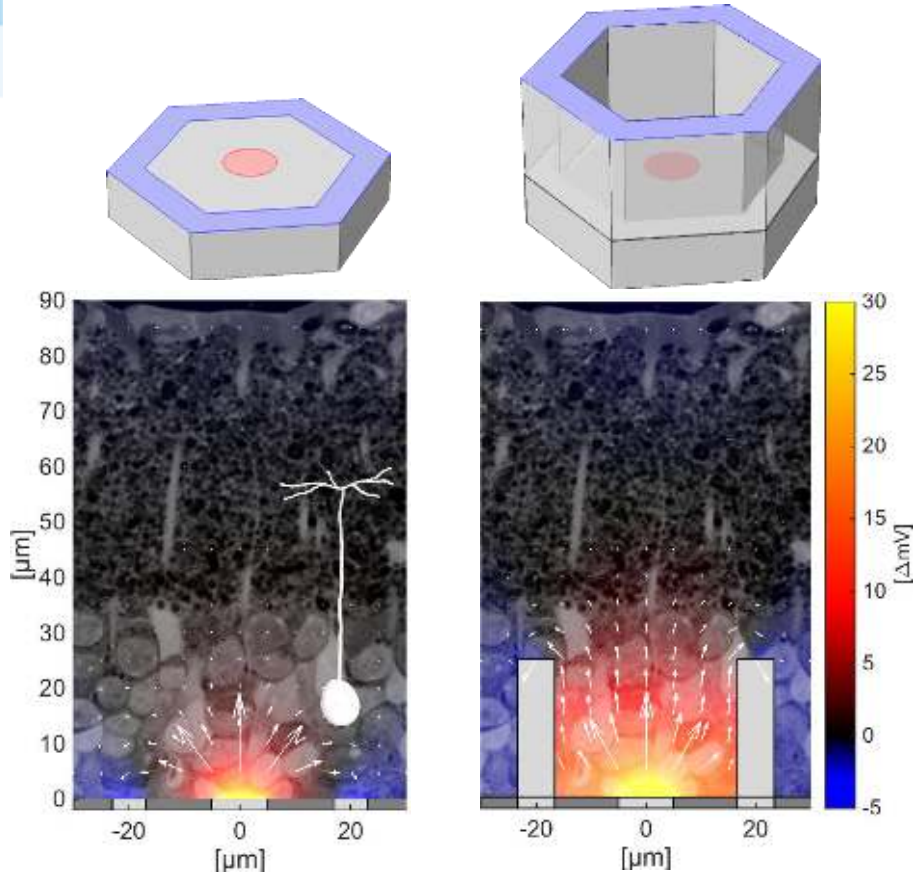
- Patients preferred frequency: 10 Hz and above (30 Hz).
- Minimum bar width: 1 pixel in all 4 patients with subretinal placement, 2 pixels in one patient with intra-choroidal placement of the implant.
- Bar orientation: 88-96% correct in all 4 patients with subretinal placement.
- **Visual acuity measured with Landolt C is only 10-30% below the theoretical minimum for the 100 μm pixel size:**

Theoretical maximum with 100 μm pixels	20/420 (1.32 logMAR), 1.0 pixel
Patient 2, pre-op: 20/800 (1.6 LogMAR)	20/550 (1.44 logMAR), 1.35 pixels
Patient 3, pre-op: 20/1000 (1.7 LogMAR)	20/500 (1.40 logMAR), 1.23 pixels
Patient 5, pre-op: 20/500 (1.4 LogMAR)	20/460 (1.37 logMAR), 1.15 pixels

Opaque video goggles with a camera



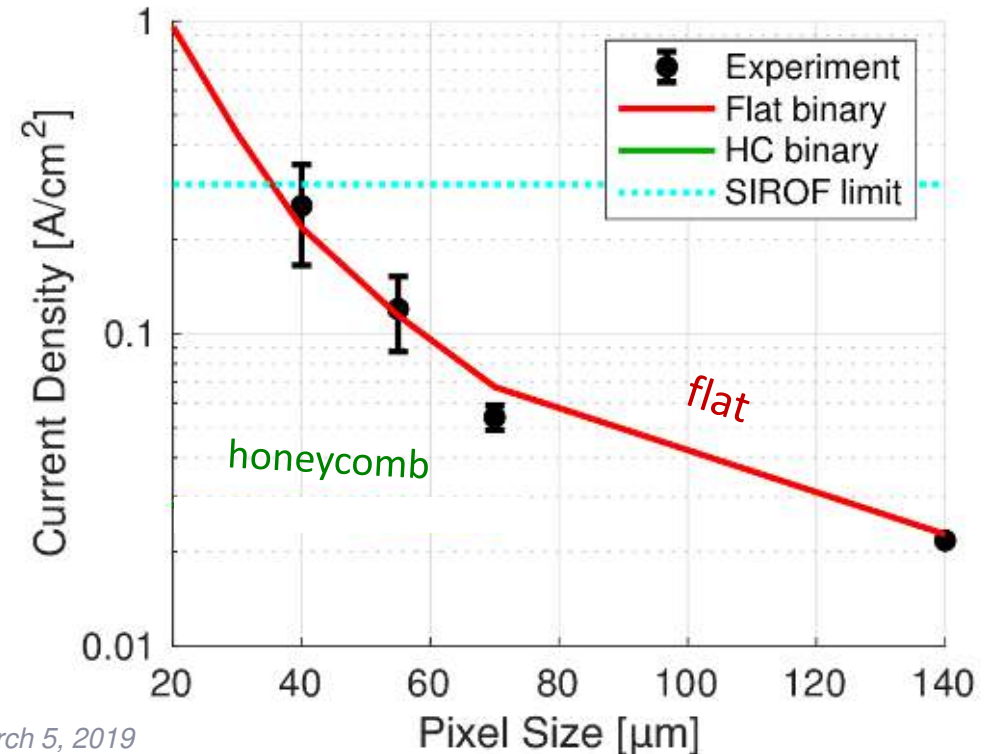
Smaller pixels enabled by honeycomb arrays



- Stimulation thresholds greatly reduced
- **Penetration depth and stimulation threshold do not depend on pixel width!**


$$DV = E \cdot l = j \cdot r \cdot l,$$

j - current density, r - tissue resistivity,
 l - length of the cell.




Honeycomb Arrays


40 μm



30 μm

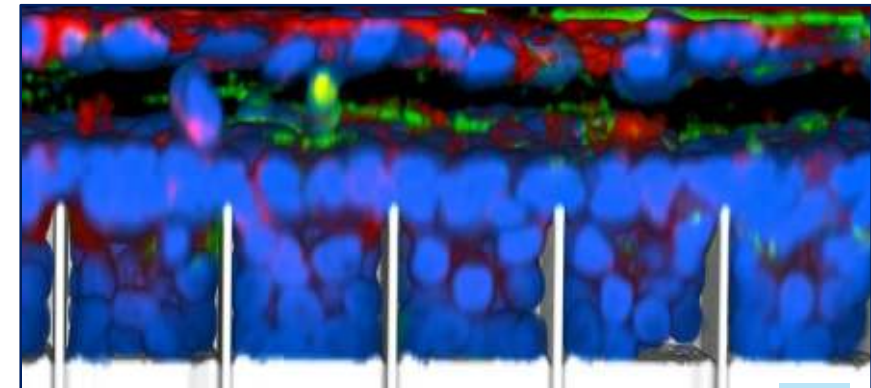

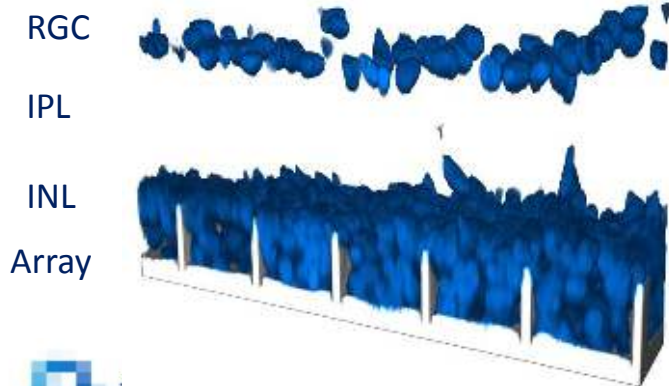


20 μm



6 weeks post implantation in RCS rats



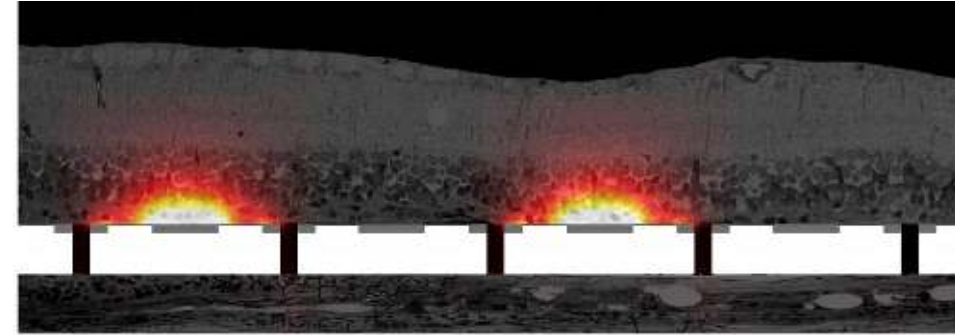
DAPI – all nuclei, IBA1- microglia, GS -Müller glia



KOL Meeting - Paris - March 5, 2019

Summary

- ✓ Subretinal pixels larger than $70\ \mu\text{m}$ provide sufficient penetration of electric field into the inner retina.
- ✓ Clinical results with PRIMA™ ($100\ \mu\text{m}$ pix) are very encouraging.
- ✓ Pixels smaller than $50\ \mu\text{m}$ will be based on honeycomb arrays.
- ✓ Ultimate goal: to achieve visual acuity $>20/100$ using $20\ \mu\text{m}$ honeycomb pixels. About 10,000 pixels in a 2 mm array.



First in human study PRIMA in AMD

José-Alain Sahel, MD


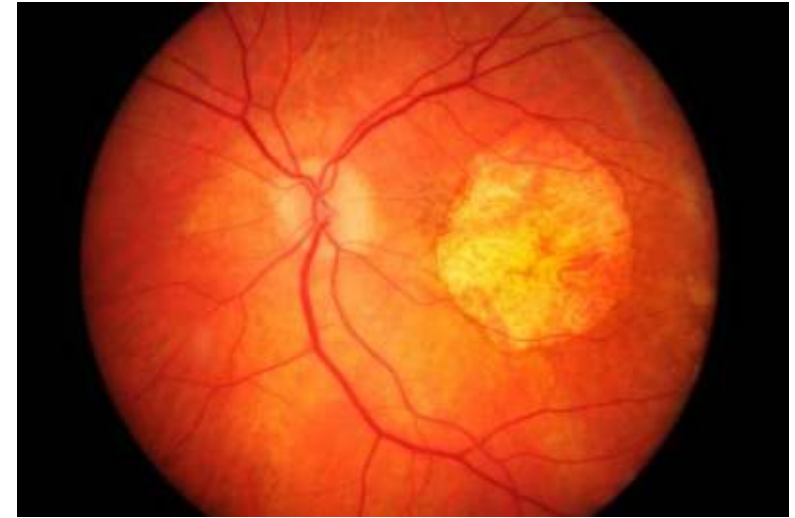
Professor and Chairman of the Department of Ophthalmology at University of Pittsburgh Medical Center (UPMC), USA

Director of the Institut de la Vision (Sorbonne-Université/Inserm/CNRS), Paris

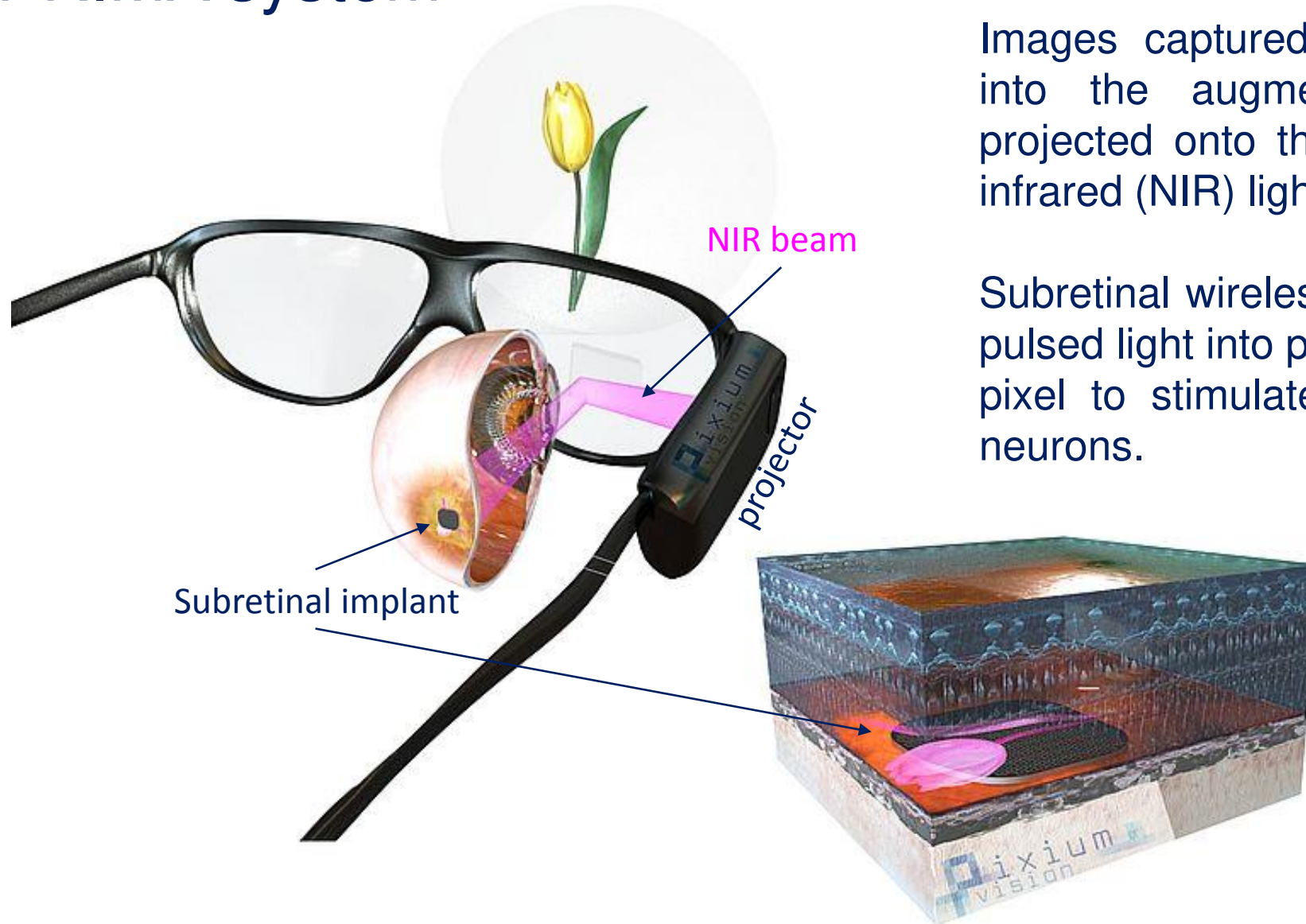
Chairman of the Department of Ophthalmology at Centre Hospitalier National d'Ophtalmologie des XV-XX, and Fondation ophtalmologique Rothschild, Paris

PRIMA System

- Designed to restore central vision within geographic atrophy.
- Wireless subretinal chip with photodiodes activated by near-infrared (NIR) light projected from video glasses, Invented by Daniel Palanker (Stanford)
- PRIMA chip replaces the lost photoreceptors and stimulates the bipolar cells in the INL.
- The remaining retinal network preserves many features of the natural signal processing.



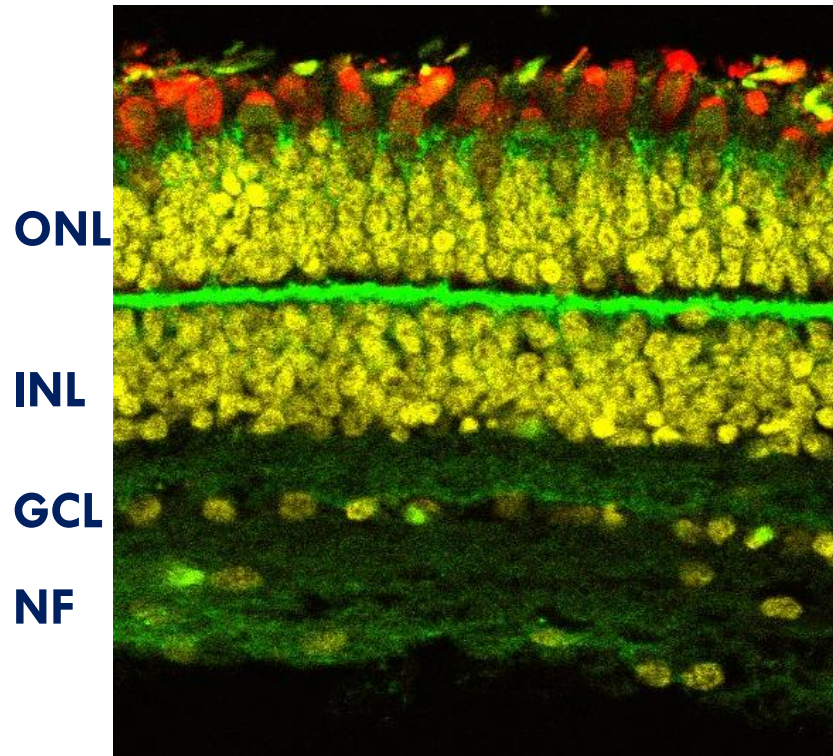
PRIMA system




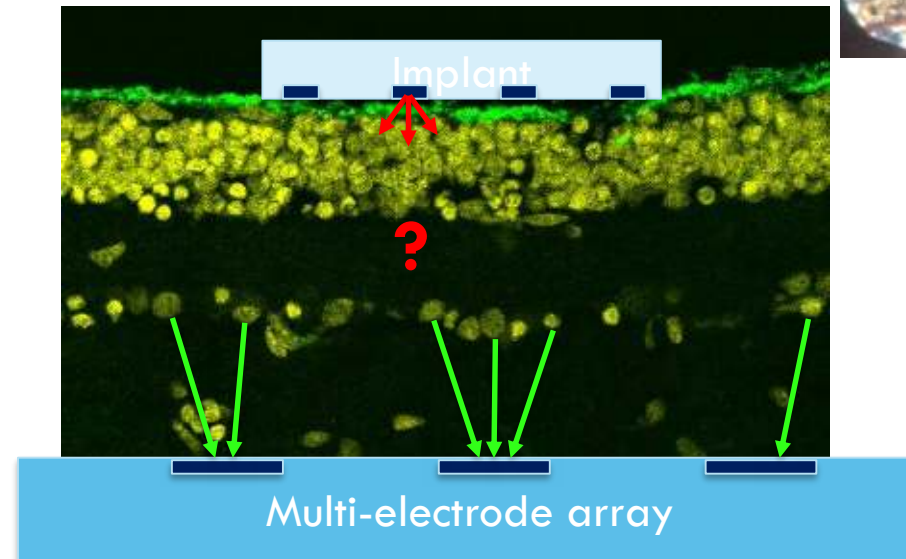
Images captured by the camera integrated into the augmented reality glasses are projected onto the retina using pulsed near-infrared (NIR) light.

Subretinal wireless photovoltaic chip converts pulsed light into pulsed electric current in each pixel to stimulate the adjacent inner retinal neurons.

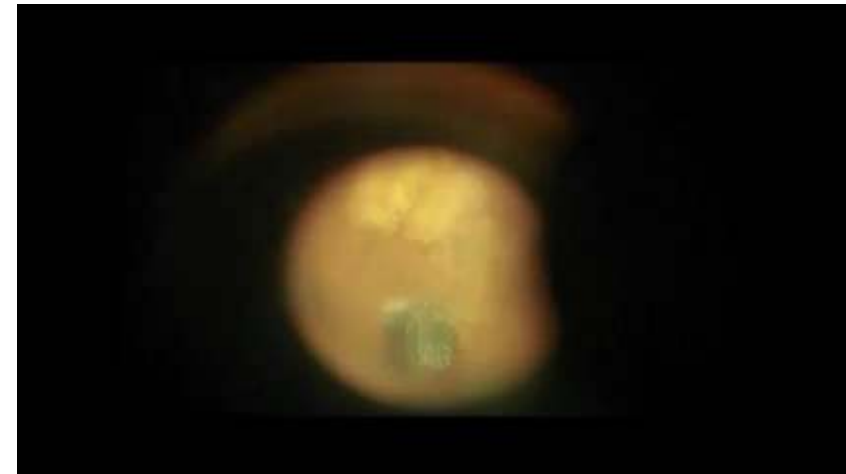
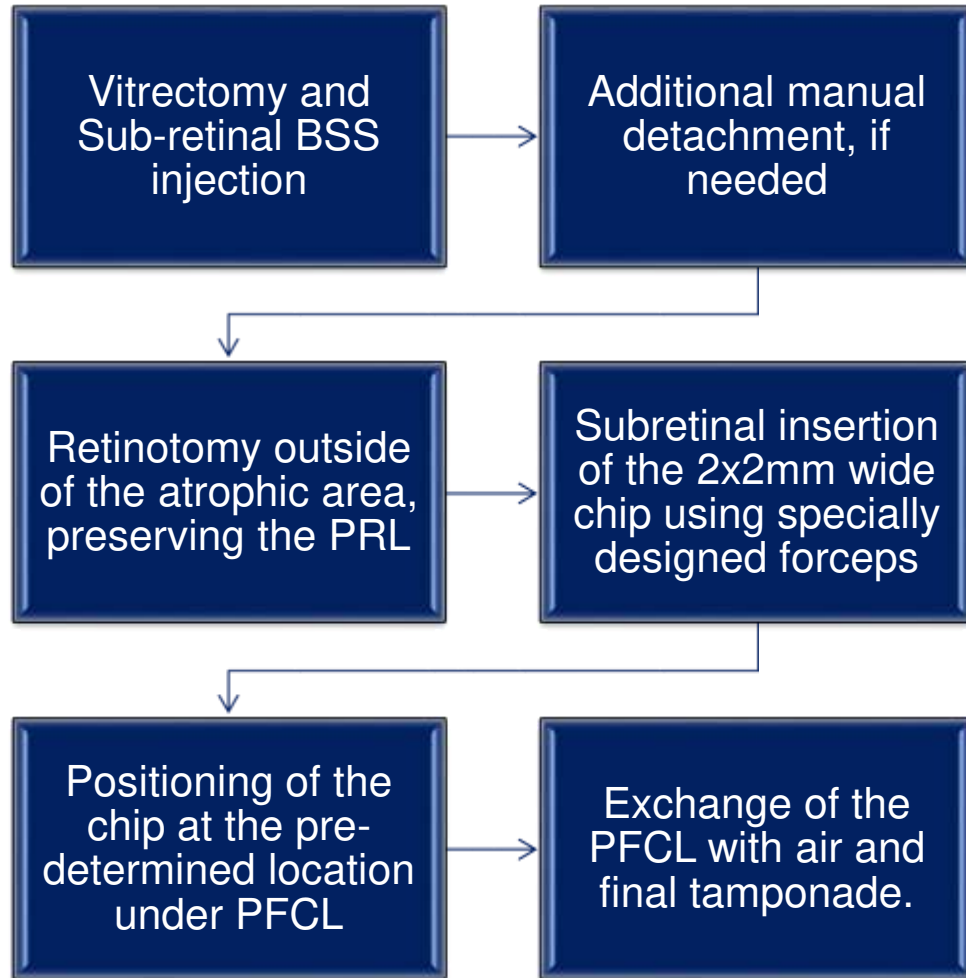
Generating an ex vivo model of a degenerated primate retina



Vibratome section of the retina



Surgical procedure



Early feasibility study design: safety and functionality

FEASIBILITY STUDY

Restoration of visual function in patients with advanced atrophic dry age related macular degeneration using the PRIMA system: open-label, non-randomized

CRITERIA

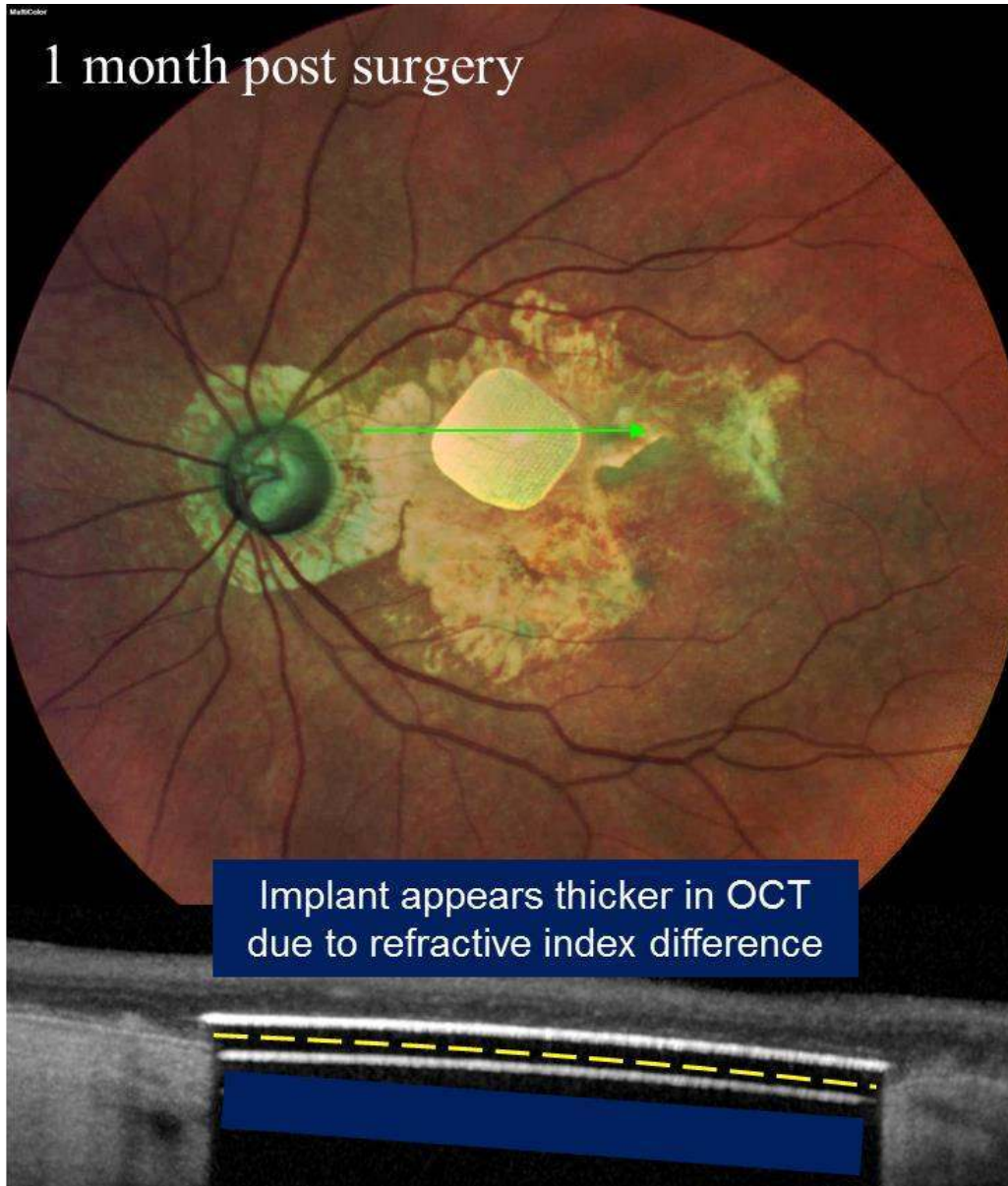
- 5 eyes of 5 patients
- VA < 20/400
- GA of at least 3 Optic Disc Diameters without any other pathology
- No light perception in the atrophic area
- Fellow eye with useful vision

PRIMARY ENDPOINT

Safety and elicitation of visual perception by electrical stimulation of the PRIMA implant measured by Octopus Visual Field.


Microperimetry to :

- Confirm the absolute scotoma in the atrophic area
- Identify the main PRL to ensure its preservation



PRIMA implant:

2x2 mm array, 30 μm thick,
with 378 pixels of 100 μm

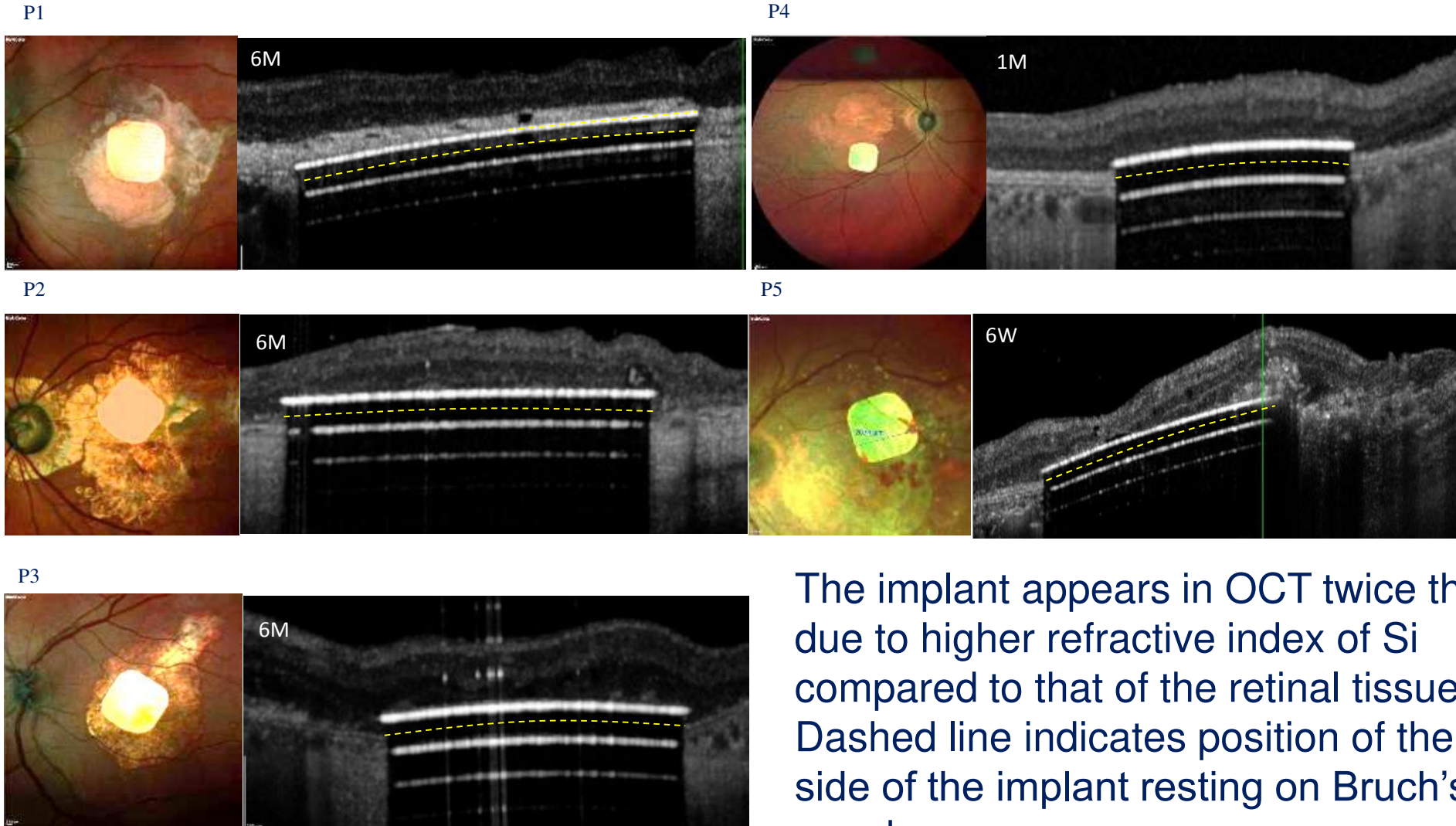


Implant is located in the middle of the geographic atrophy area, in close proximity to the INL.

Results

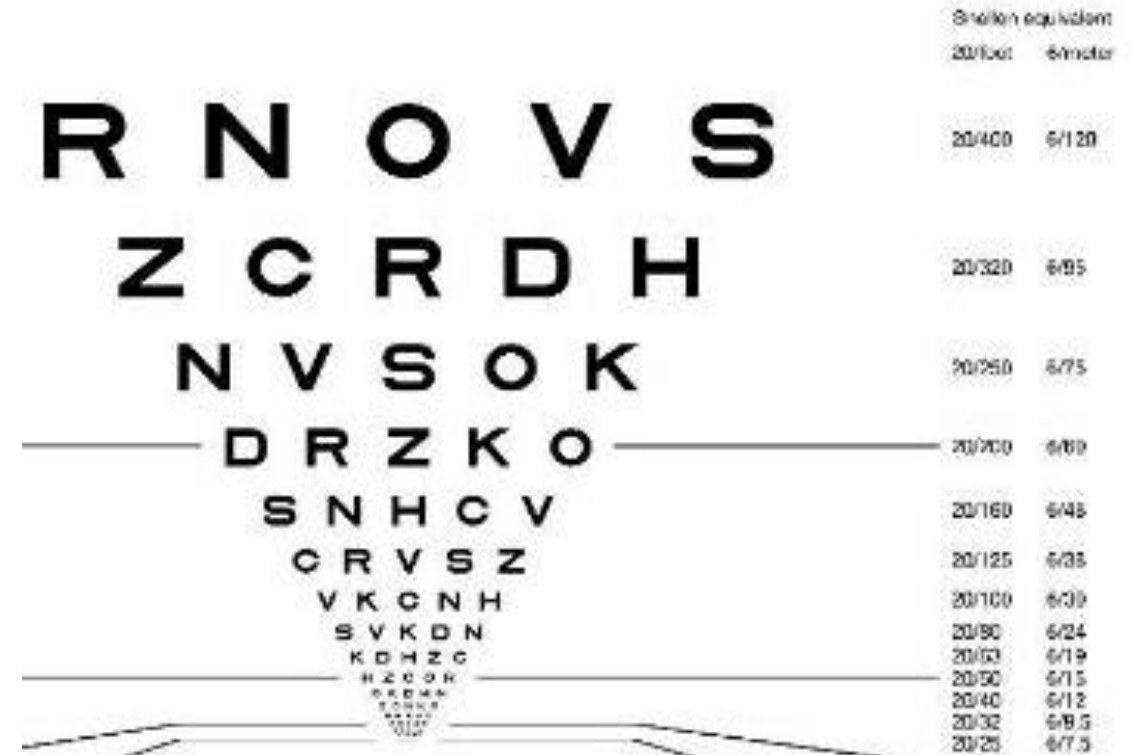
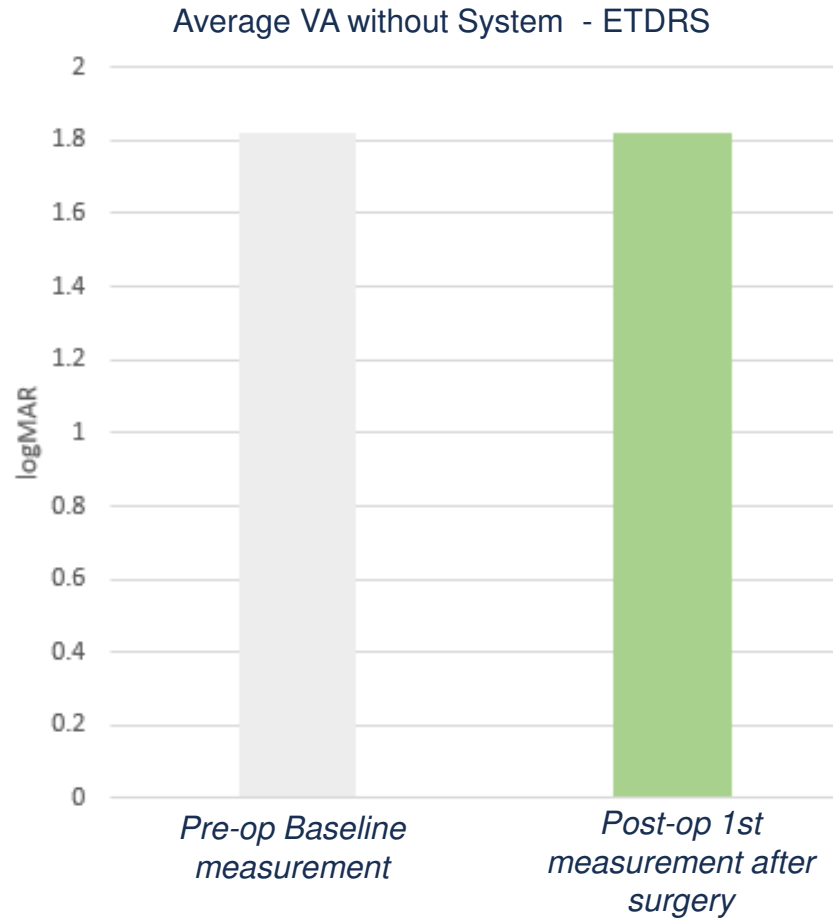
- 5 consecutive patients successfully implanted between December 2017 and June 2018 in Paris:
 - 3 with silicone oil removed at week 4 / 2 with gas (C2F6 and SF6).
- Surgery duration < 2 hours.
- Complications:
 - 1 intraoperative complication: movement of the patient head under local anesthesia during implantation led to thin subretinal bleeding, which resolved after 6 weeks.
 - 1 SAE at day 1 - acute hypertony resolved 2 days later without consequence.
 - 1 small migration of the chip due to early posture change after surgery. The chip remained within the atrophic area.
 - 1 retinal detachment one year after surgery, retina reattached, no impact on implant

Anatomical Results




The implant appears in OCT twice thicker due to higher refractive index of Si compared to that of the retinal tissue. Dashed line indicates position of the back side of the implant resting on Bruch's membrane.

Visual acuity (ETDRS) Pre vs. Post implantation



PRIMA can be safely implanted under the atrophic macula while preserving the residual natural peripheral visual acuity, measured via ETDRS

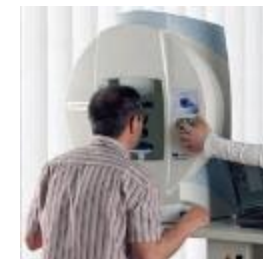
Results



- No other serious post-operative complications during the follow up currently ranging from 4 to 10 months.
- No decrease in natural vision compared to pre-operative acuity.
- Patients are trained to use the system and progress to describe patterns, objects, letters, etc. elicited via the PRIMA chip in atrophic areas of the macula.
- Objective vision tests were conducted using opaque glasses to prevent confusion with residual natural vision.

PRIMA central visual perception at 6 Months

- Octopus Visual Field Measurement*
- Fully opaque glasses: light perception via PRIMA chip only



*performance of the PRIMA chip and system without use of any peripheral remaining vision (only with fully opaque glasses)

Tests of Prosthetic Vision




Acuity measured with Landolt C

Theoretical limit with 100 μm pixels	20/400 (1.30 logMAR), 1.0 pixel
Subject A : PRE-OP : CF	20/550 (1.44 logMAR), 1.35 pixels
Subject B : PRE-OP : HM	20/500 (1.40 logMAR), 1.23 pixels
Subject C : PRE-OP LogMAR 1.4	20/460 (1.37 logMAR), 1.15 pixels

15-35% below the theoretical limit of resolution for 100 μm pixels

Control: System ON vs OFF



It looks like a "4"

Conclusions

- Subretinal implantation of the wireless PRIMA chip in atrophic dry AMD is feasible and safe.
- No decrease in residual natural vision compared to pre-operative visual acuity.
- ALL 5 patients reached the functional primary end point of the feasibility study (visual perception in the former scotoma).
- PRIMA provided the best prosthetic visual acuity to date: 20/460 – only 15% below the theoretical limit for 100mm pixels.
- Most subjects recognize complex patterns close to the theoretical limit of the implant resolution.

Next Steps

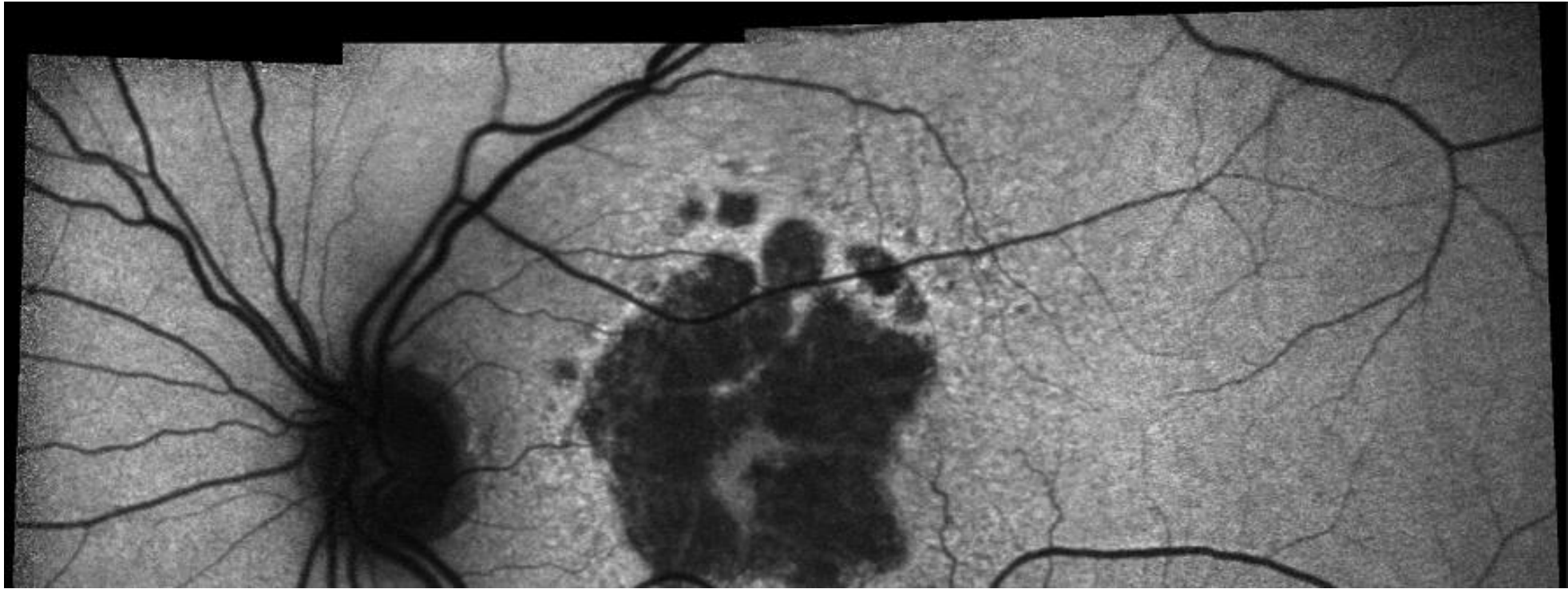
- Similar feasibility study initiated in Pittsburgh, USA (J. Martel, J.A. Sahel).
- European multicenter pivotal study is planned for 2019.
- Implants with smaller pixels are being developed and tested in preclinical studies (Palanker's group at Stanford).

Real world unmet medical need: Atrophic dry-AMD

Frank G. Holz, MD

Chairman and Professor, Department of Ophthalmology, University of Bonn, Germany

President Elect of European Society of Retinal Specialists (EURETINA)

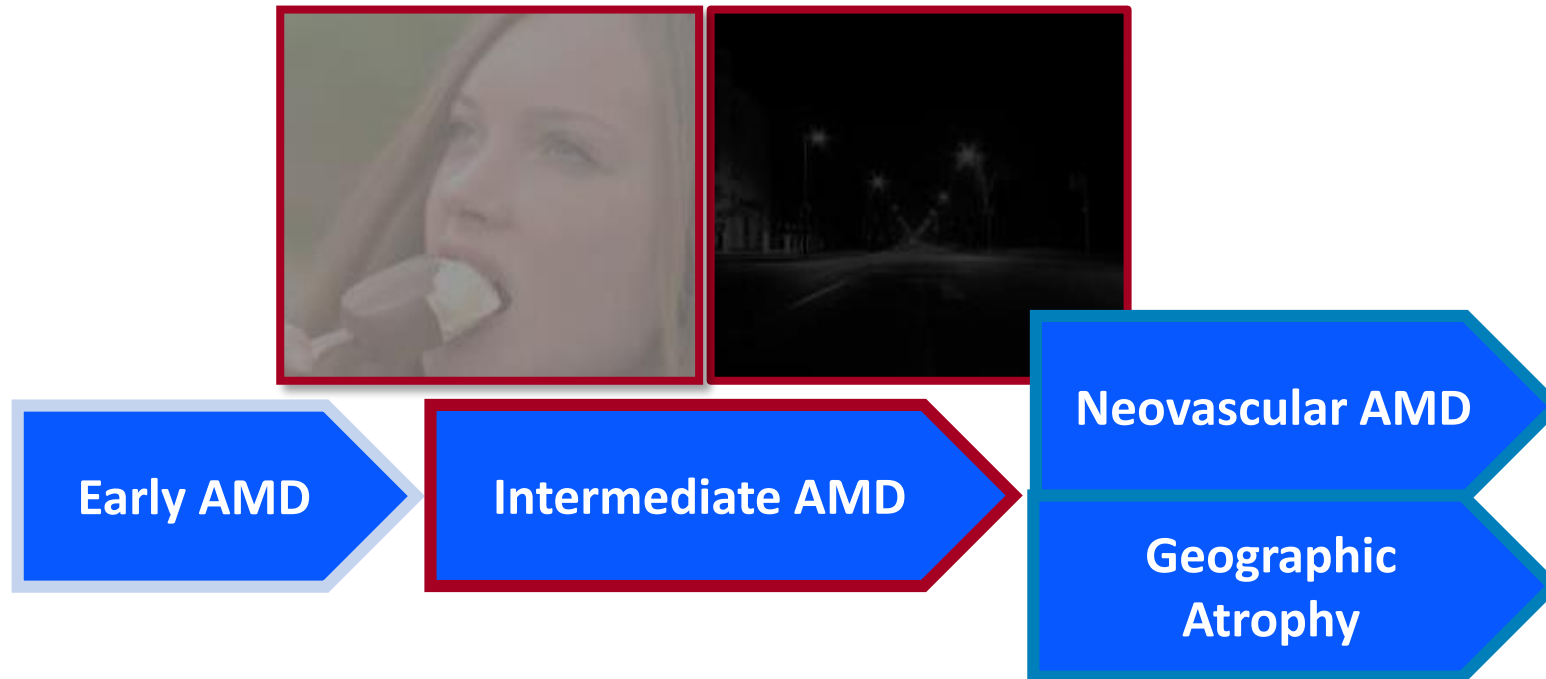


universität**bonn** **ukb** universitäts
klinikum**bonn** **UNIVERSITÄTS
AUGENKLINIK**Bonn

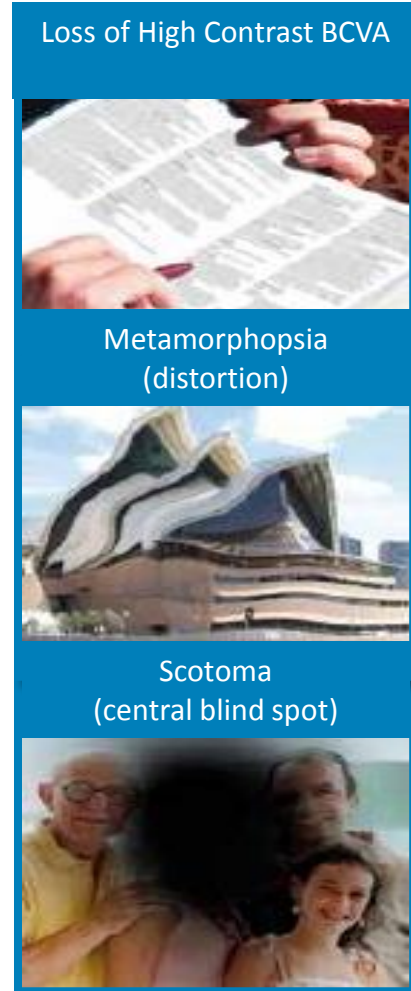
Dry AMD /Geographic Atrophy

Frank G. Holz
University of Bonn, Germany

AMD Progressive Visual Impairment

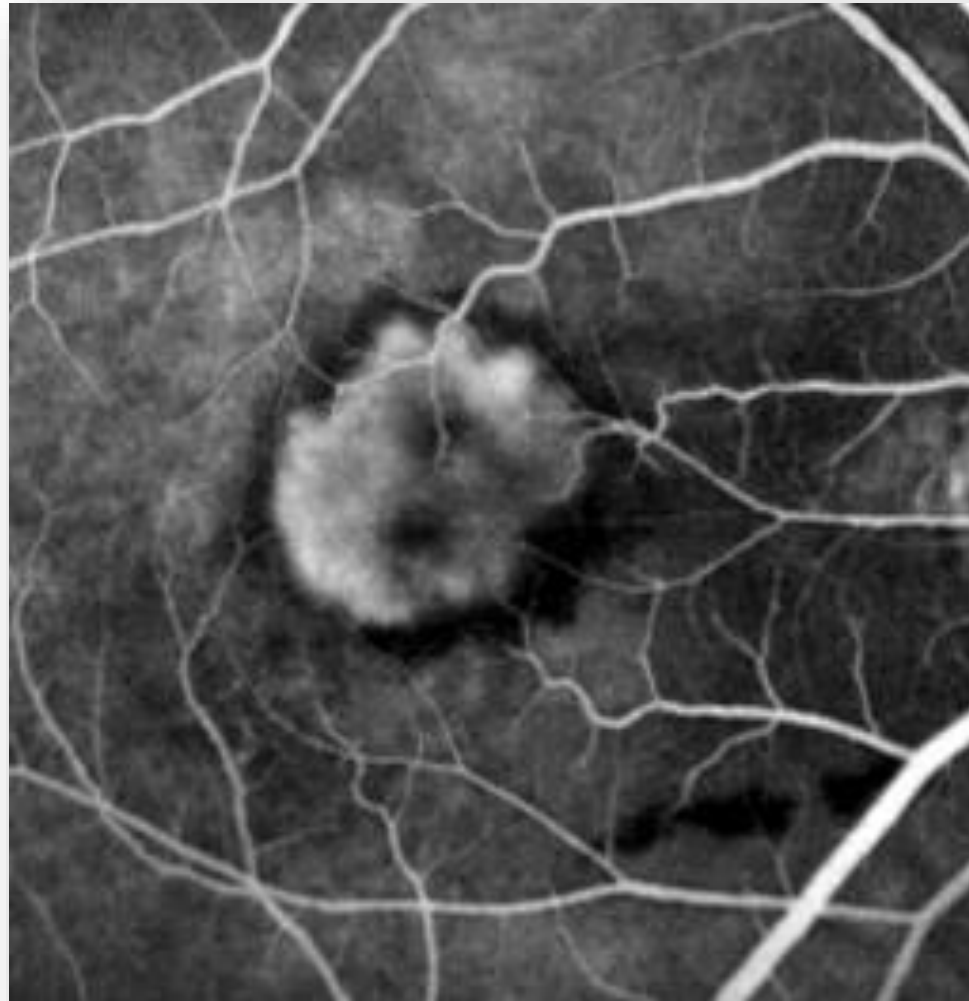

- » **Late AMD** severe loss of vision, independence, and quality of life, increased rates of falls, depression, and institutionalization



Therapy neovascular AMD

Introduction anti-VEGF-Therapy 10 years ago



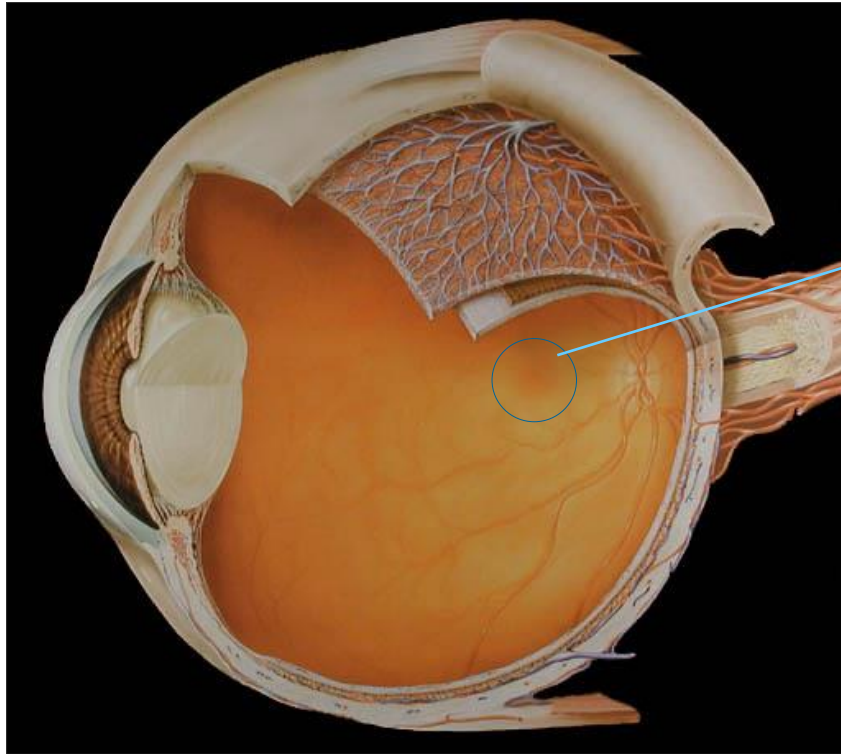
KOL Meeting - Paris - March 5, 2019

Age-related macular degeneration (AMD)

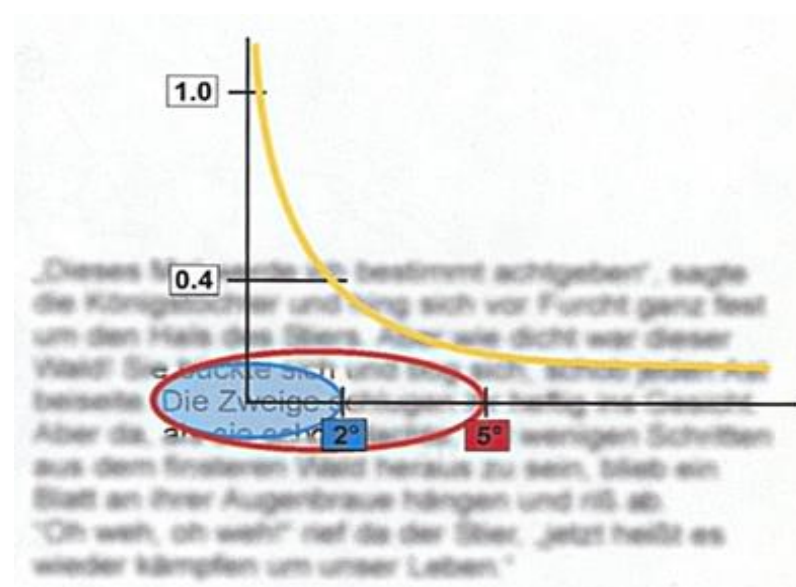
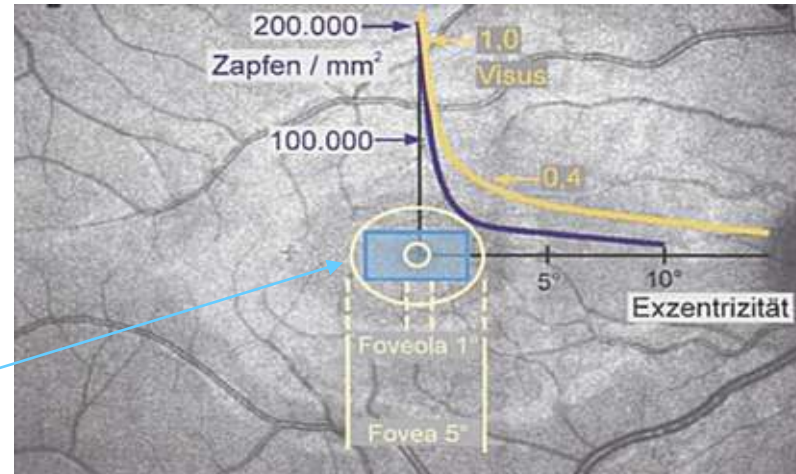
Dry AMD – major unmet need

- Leading cause of blindness
- Even with effective treatments for neovascular AMD, atrophy is still the long-term outcome
- Chronic progressive neurodegenerative disease
- Many challenges including multifactorial pathogenesis

Macular Function

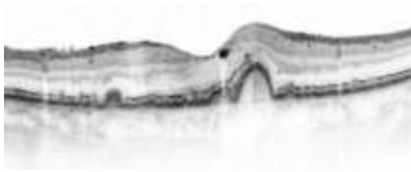
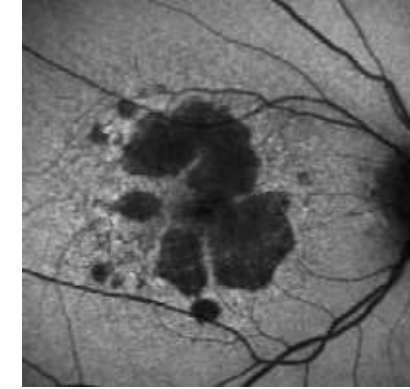
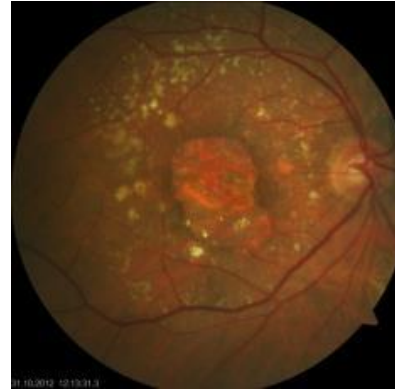
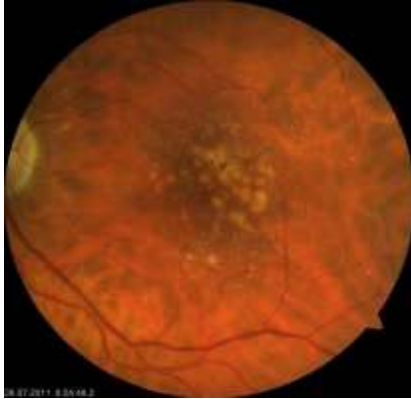
Courtesy S. Trauzettel-Klosinski






“Dry” Age-related macular degeneration (AMD)



Drusen
Pigment abnormalities

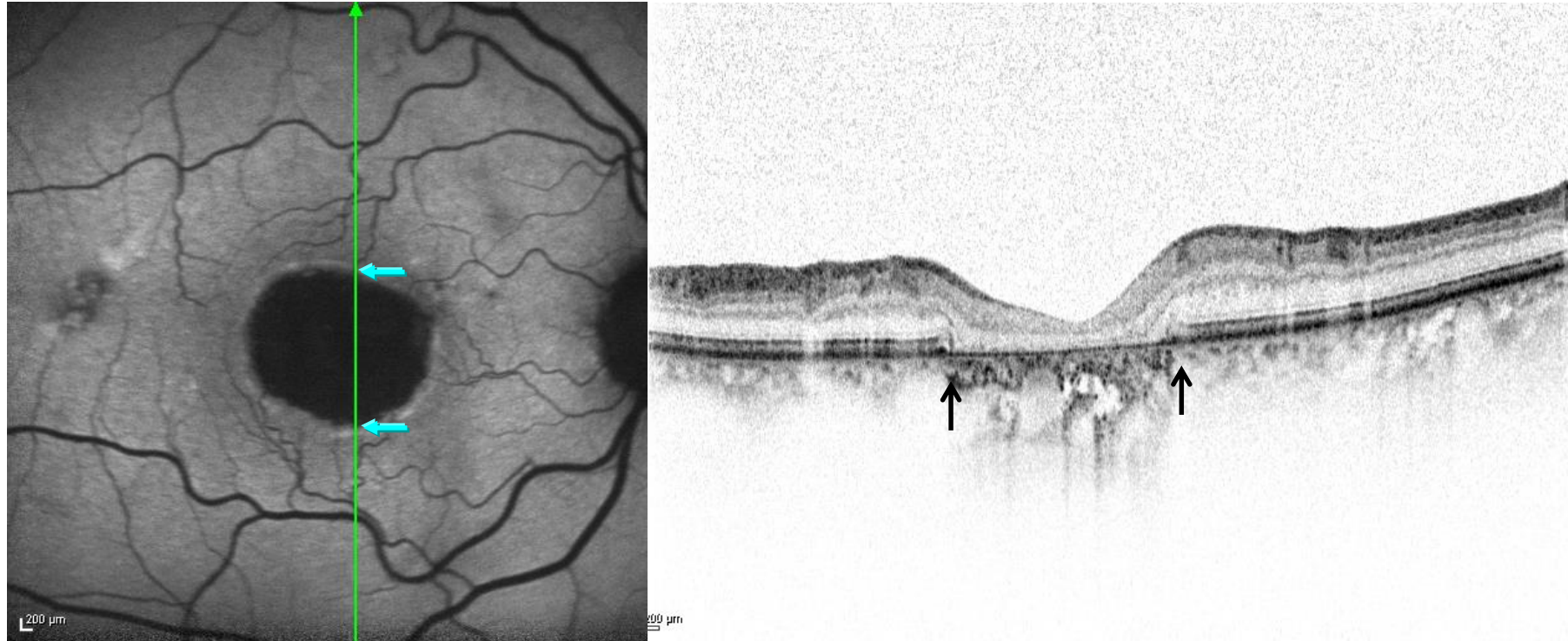
Early/intermediate AMD

“Geographic atrophy“



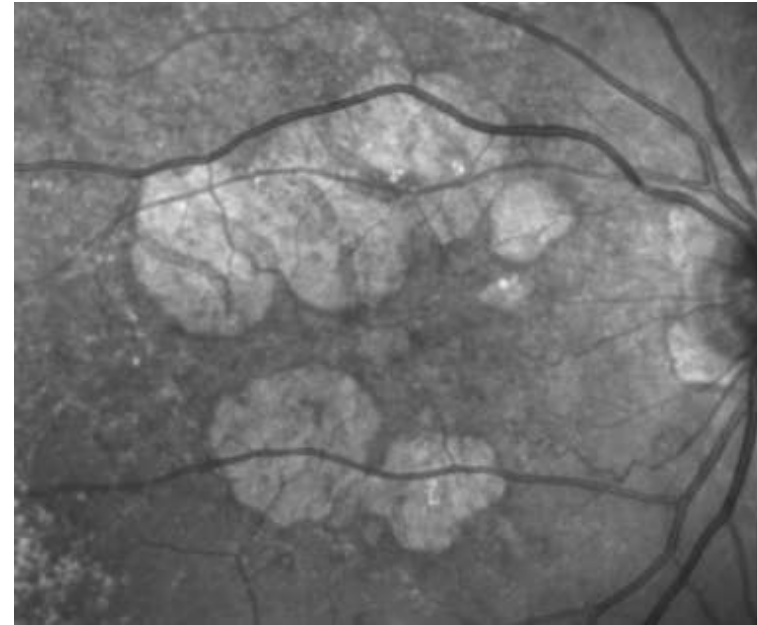
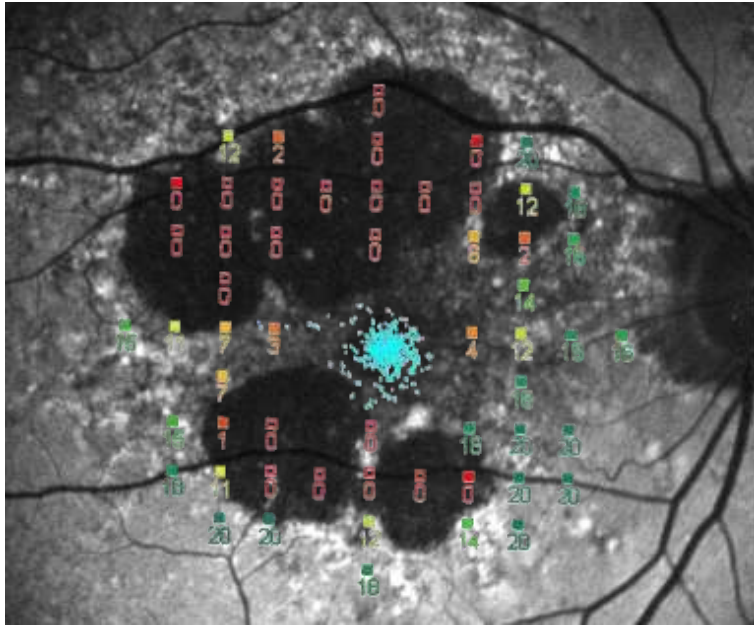
Late-stage AMD

Loss of RPE on FAF correlates with photoreceptor loss on SD-OCT

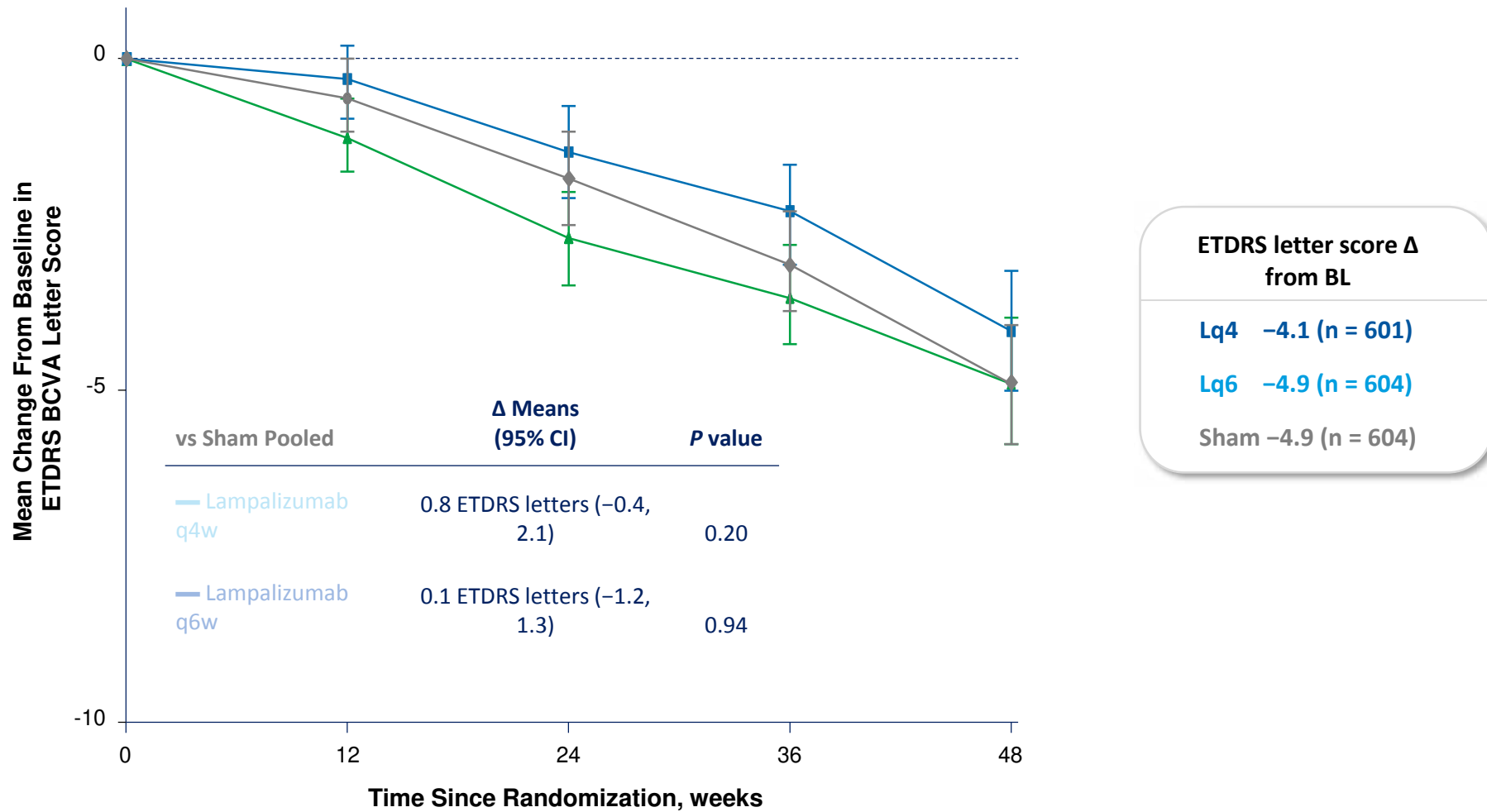


S Schmitz-Valckenberg, M Fleckenstein, AP Göbel, TC Hohman, FG Holz. IOVS 52:1-6;2011

Loss of RPE in FAF images correlates with loss of photoreceptor function on microperimetry



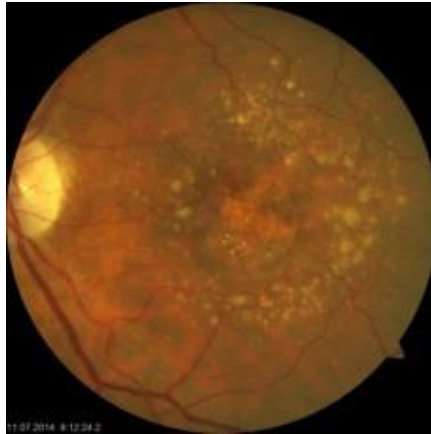Spectri and Chroma Pooled Outcome: Change in Best-Corrected Visual Acuity from Baseline to Week 48



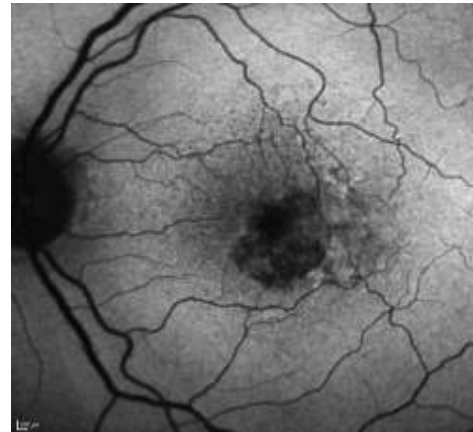
Holz FG, Sada SR, Busbee B, Chew EY, Mitchell P, Tufail A, Brittain C, Ferrara D, Gray S, Honigberg L, Martin J, Tong B, Ehrlich JS, Bressler NM; Chroma and Spectri Study Investigators. JAMA Ophthalmol. 2018 May 2

Structural Assessment - Imaging Modalities

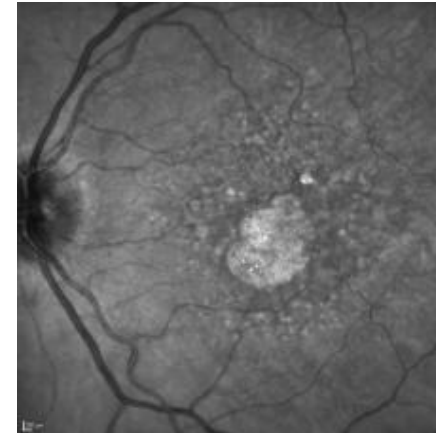
Colour fundus photography



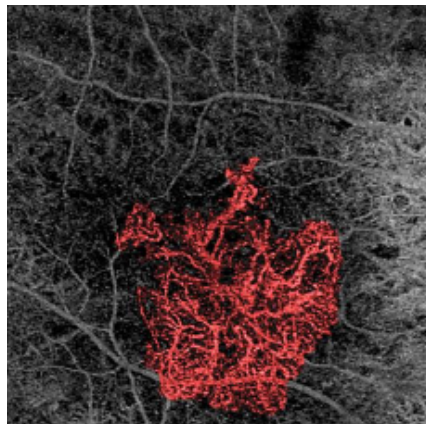
Fundus autofluorescence



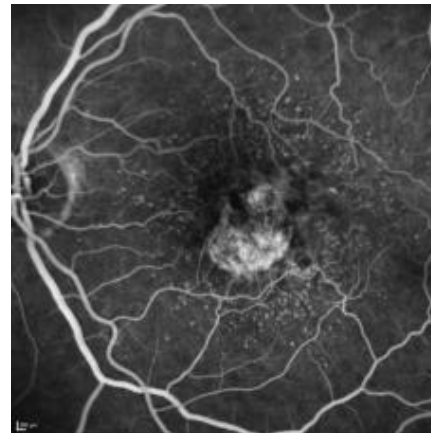
Near-infrared reflectance



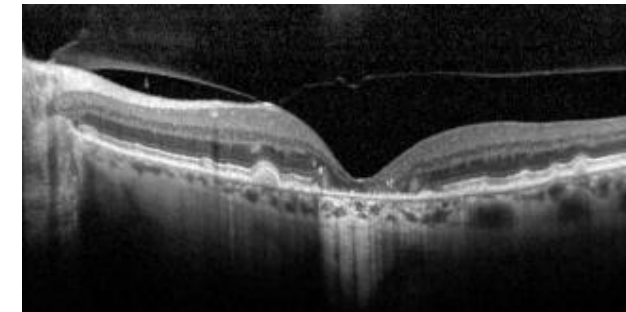
OCT-Angiography



Fluorescein angiography



SD-OCT/SS-OCT



Imaging Protocols in Clinical Studies in Advanced Age-Related Macular Degeneration

Recommendations from Classification of Atrophy Consensus Meetings

Frank G. Holz, MD, FEBO,¹ Srinivas R. Sadda, MD,² Giovanni Staurenghi, MD, FARVO,³ Moritz Lindner, MD,¹ Alan C. Bird, MD, FARVO,⁴ Barbara A. Blodi, MD,⁵ Ferdinando Bottoni, MD, FEBO,³ Usha Chakravarthy, MBBS, PhD,⁶ Emily Y. Chew, MD, FARVO,⁷ Karl Csaky, MD, PhD,⁸ Christine A. Curcio, PhD, FARVO,⁹ Ron Davis, MD,⁵ Monika Fleckenstein, MD,¹ K. Bailey Freund, MD,¹⁰ Juan Grunwald, MD,¹¹ Robyn Guymer, MBBS, PhD,¹² Carel B. Hoyng, MD, PhD,¹³ Glenn J. Jaffe, MD, FARVO,¹⁴ Samira Liakopoulos, MD,¹⁵ Jordi M. Monés, MD, PhD,¹⁶ Akio Oishi, MD, PhD,¹ Daniel Paulekhoff, MD,¹⁷ Philip J. Rosenfeld, MD, PhD,¹⁸ David Sarraf, MD,¹⁹ Richard F. Spaide, MD,¹⁰ Ramin Tadayoni, MD, PhD,²⁰ Adnan Tufail, MD, FRCOphth,²¹ Sebastian Wolf, MD, PhD,²² Steffen Schmitz-Valckenberg, MD, FEBO,¹ on behalf of the CAM group*

Purpose: To summarize the results of 2 consensus meetings (Classification of Atrophy Meeting [CAM]) on conventional and advanced imaging modalities used to detect and quantify atrophy due to late stage non neovascular and neovascular age related macular degeneration (AMD) and to provide recommendations on the use of these modalities in natural history studies and interventional clinical trials.

Design: Systematic debate on the relevance of distinct imaging modalities held in 2 consensus meetings.

Participants: A panel of retina specialists.

Methods: During the CAM, a consortium of international experts evaluated the advantages and disadvantages of various imaging modalities on the basis of the collective analysis of a large series of clinical cases. A systematic discussion on the role of each modality in future studies in non neovascular and neovascular AMD was held.

Main Outcome Measures: Advantages and disadvantages of current retinal imaging technologies and recommendations for their use in advanced AMD trials.

Results: Imaging protocols to detect, quantify, and monitor progression of atrophy should include color fundus photography (CFP), confocal fundus autofluorescence (FAF), confocal near infrared reflectance (NIR), and high resolution optical coherence tomography volume scans. These images should be acquired at regular intervals throughout the study. In studies of non neovascular AMD (without evident signs of active or regressed neovascularization [NV] at baseline), CFP may be sufficient at baseline and end of study visit. Fluorescein angiography (FA) may become necessary to evaluate for NV at any visit during the study. Indocyanine green angiography (ICG A) may be considered at baseline under certain conditions. For studies in patients with neovascular AMD, increased need for visualization of the vasculature must be taken into account. Accordingly, these studies should include FA (recommended at baseline and selected follow up visits) and ICG A under certain conditions.

Conclusions: A multimodal imaging approach is recommended in clinical studies for the optimal detection and measurement of atrophy and its associated features. Specific validation studies will be necessary to determine the best combination of imaging modalities, and these recommendations will need to be updated as new imaging technologies become available in the future. *Ophthalmology* 2017;124:464-478 © 2017 by the American Academy of Ophthalmology



*Supplemental material available at www.aaojournal.org.

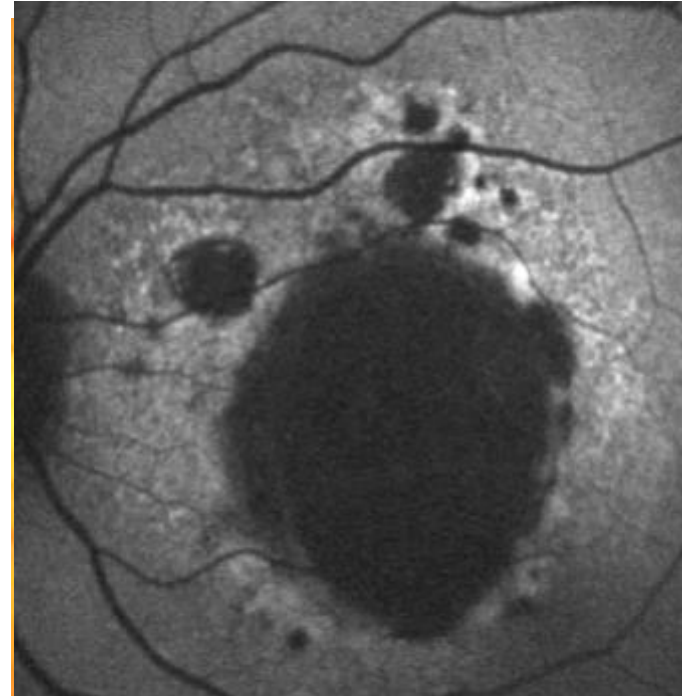
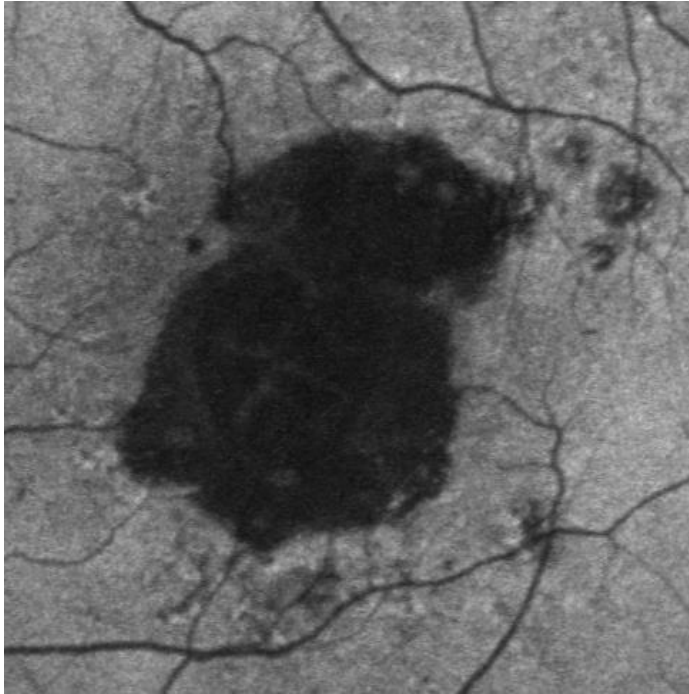


Consensus Definition for Atrophy Associated with Age-Related Macular Degeneration on OCT

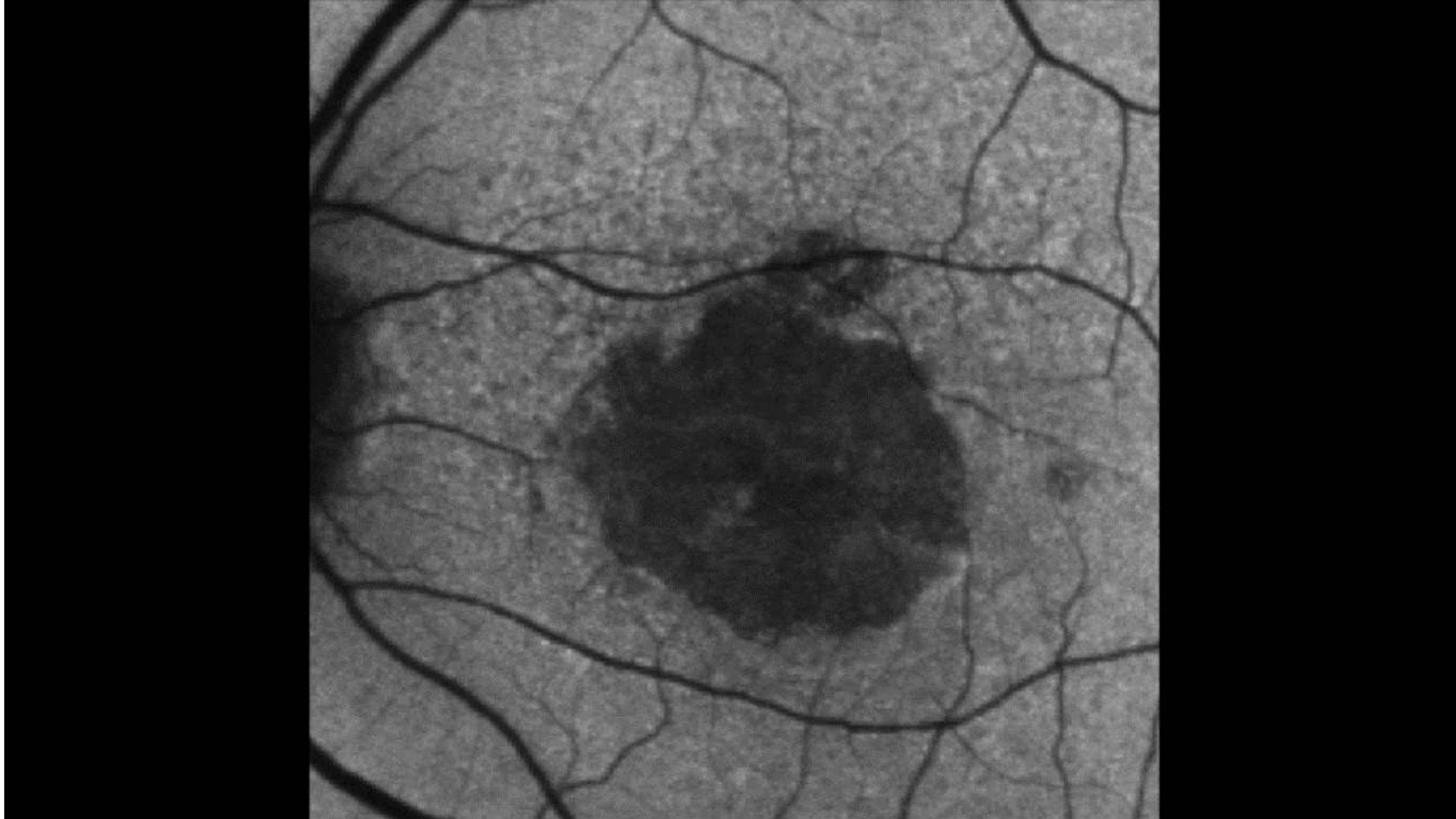
Classification of Atrophy Report 3

Srinivas R. Sadda, MD,¹ Robyn Guymer, MBBS, PhD,² Frank G. Holz, MD,³ Steffen Schmitz-Valckenberg, MD,³ Christine A. Curcio, PhD,⁴ Alan C. Bird, MD,⁵ Barbara A. Blodi, MD,⁶ Ferdinando Bottoni, MD, FEBO,⁷ Usha Chakravarthy, MD, PhD,⁸ Emily Y. Chew, MD,⁹ Karl Csaky, MD,¹⁰ Ronald P. Danis, MD,⁶ Monika Fleckenstein, MD,³ K. Bailey Freund, MD,¹¹ Juan Grunwald, MD,¹² Carel B. Hoyng, MD, PhD,¹³ Glenn J. Jaffe, MD,¹⁴ Sandra Liakopoulos, MD,¹⁵ Jordi M. Monés, MD, PhD,¹⁶ Daniel Pauleikhoff, MD,¹⁷ Philip J. Rosenfeld, MD, PhD,¹⁸ David Sarraf, MD,¹⁹ Richard F. Spaide, MD,¹⁰ Ramin Tadayoni, MD, PhD,²⁰ Adnan Tufail, MD, FRCOphth,^{5,21} Sebastian Wolf, MD, PhD,²² Giovanni Staurenghi, MD, FARVO⁷

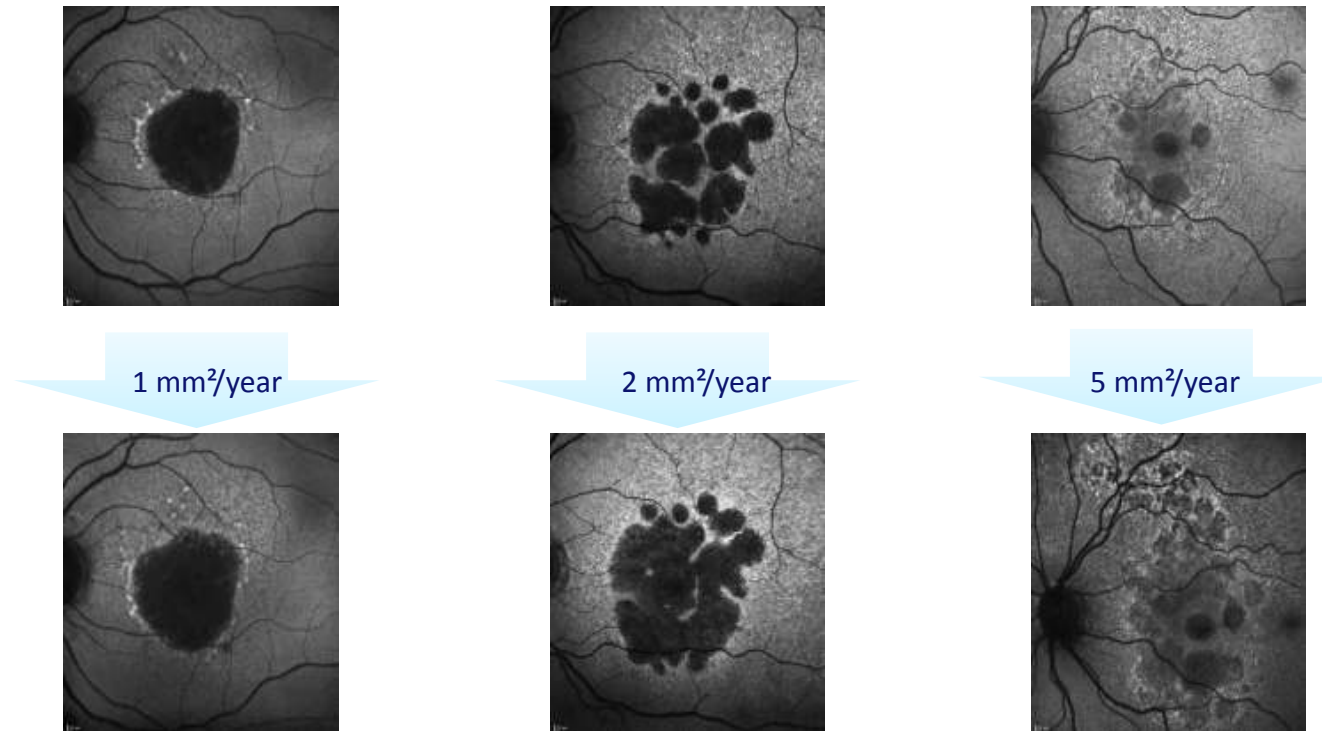
Geographic Atrophy Assessment Fundus Autofluorescence Imaging



Geographic Atrophy – Disease progression



Geographic atrophy - Prognostic markers for disease progression

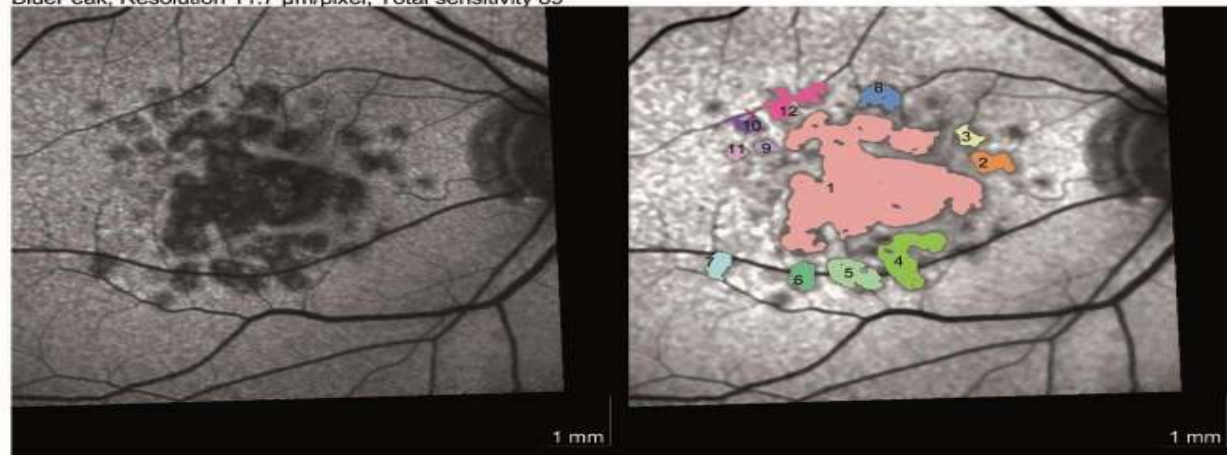


➤ High variability in GA progression rate

AREDS Lindblad et al. 2009, *BDES* Klein et al. 2008, *BMES* Joachim et al. 2013, *FAM* Holz et al. 2007, *GAIN* Biarnes et al. 2015, *GAP* Schmitz-Valckenberg et al. 2016, *GAS* Sunness et al. 1999,

Geographic Atrophy: Fundus Autofluorescence Automated Detection and Quantification

BluePeak, Resolution 11.7 $\mu\text{m}/\text{pixel}$, Total sensitivity 89



Reading Details

Date: 25.02.2011
 Time: 17:37:24
 Total region size: 6.340 mm²

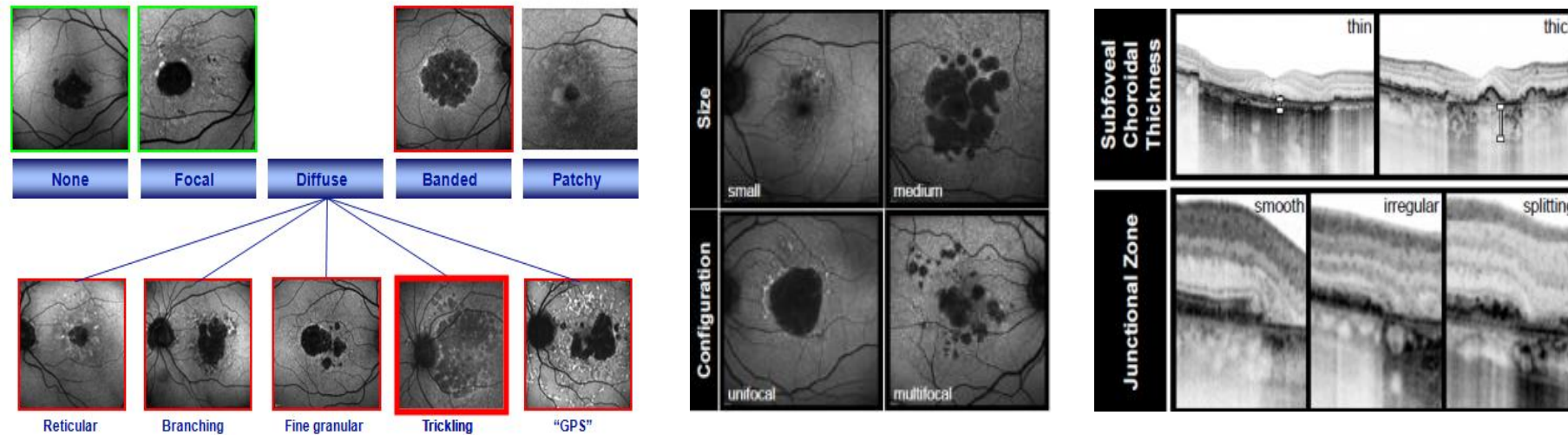
Number of regions: 12
 Perilesional pattern: unseeded
 Reader Name: [redacted]

N°	Border Color	Size [mm ²]	Growth Power [%]	Growth Limit [%]	min-max vessel [μm]	Strap Ratio
1		4.291	37	100	30 - 30	0.00
4		0.532	27	29	30 - 194	0.88
5		0.303	43	67	30 - 196	0.88
12		0.244	13	100	30 - 30	0.00
8		0.197	21	100	30 - 30	0.00
2		0.174	32	100	30 - 132	0.89
6		0.152	33	48	30 - 191	0.87
7		0.131	16	14	30 - 196	0.24
10		0.112	19	100	30 - 196	0.89
-	Aggregate	0.204	-	-	-	-

Schmitz-Valckenberg S, Brinkmann CK, Alten F, Herrmann P, Stratmann NK, Göbel AP, Fleckenstein M, Diller M, Jaffe GJ, Holz FG. *Invest Ophthalmol Vis Sci.* 2011;52:7640-6

KOL Meeting - Paris - March 5, 2019

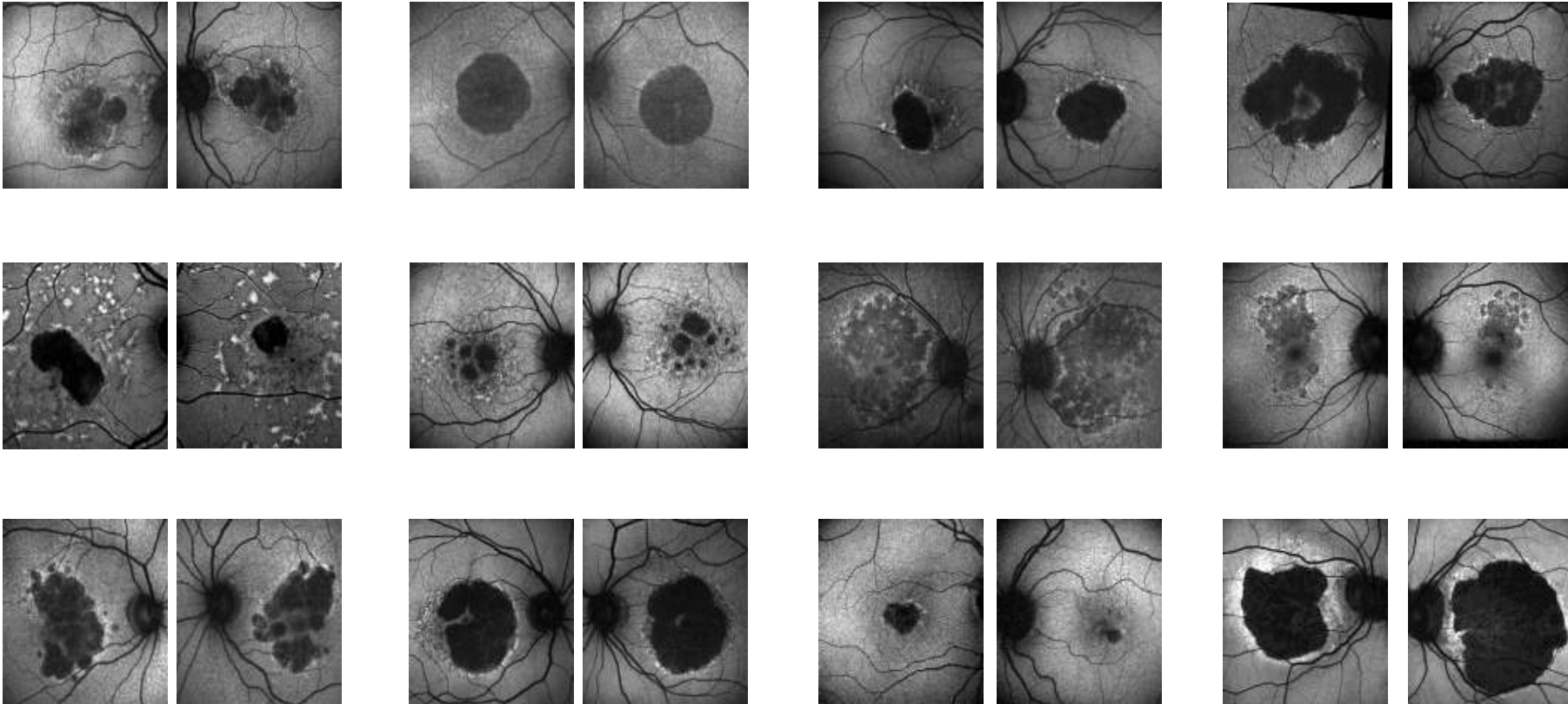
Geographic atrophy (GA) - Morphologic markers for disease progression



- Prognostic information for future disease progression
- Identification of patients at high risk losing visual acuity / reading ability
- Unequal distribution of patients with risk-features in clinical trials may counterfeit / obscure a therapeutic effect

Fleckenstein M, Mitchell P, Freund B, Sadda SR, Holz FG, Brittain C, Henry EC, Ferrara D.
Review. *Ophthalmology* 2017 S0161-6420(17)30968-5

Geographic atrophy (GA) - Heterogeneity




Fleckenstein M, Adrion C, Schmitz-Valckenberg S, Göbel AP, Bindewald-Wittich A, Scholl HP, Mansmann U, Holz FG, FAM-Study group. *Invest Ophthalmol Vis Sci.* 2010;50:3915-21

Visual Function Outcome Measures



BCVA

Patients often have sparing of central VA but still experience profound deficits in visual function



LVA

Low-luminance Acuity

My father asked me to help the two men carry the box inside

Three of my friends had never been to a circus before today

My grandfather has a large garden with fruit and vegetables


Reading speed

Major patient complaint with substantial impact; inverse correlation with GA lesion size



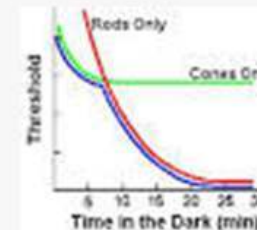
PROs (VFQ-25, FRI Index)

Visual function questionnaires measure vision-targeted health status



Micro perimetry

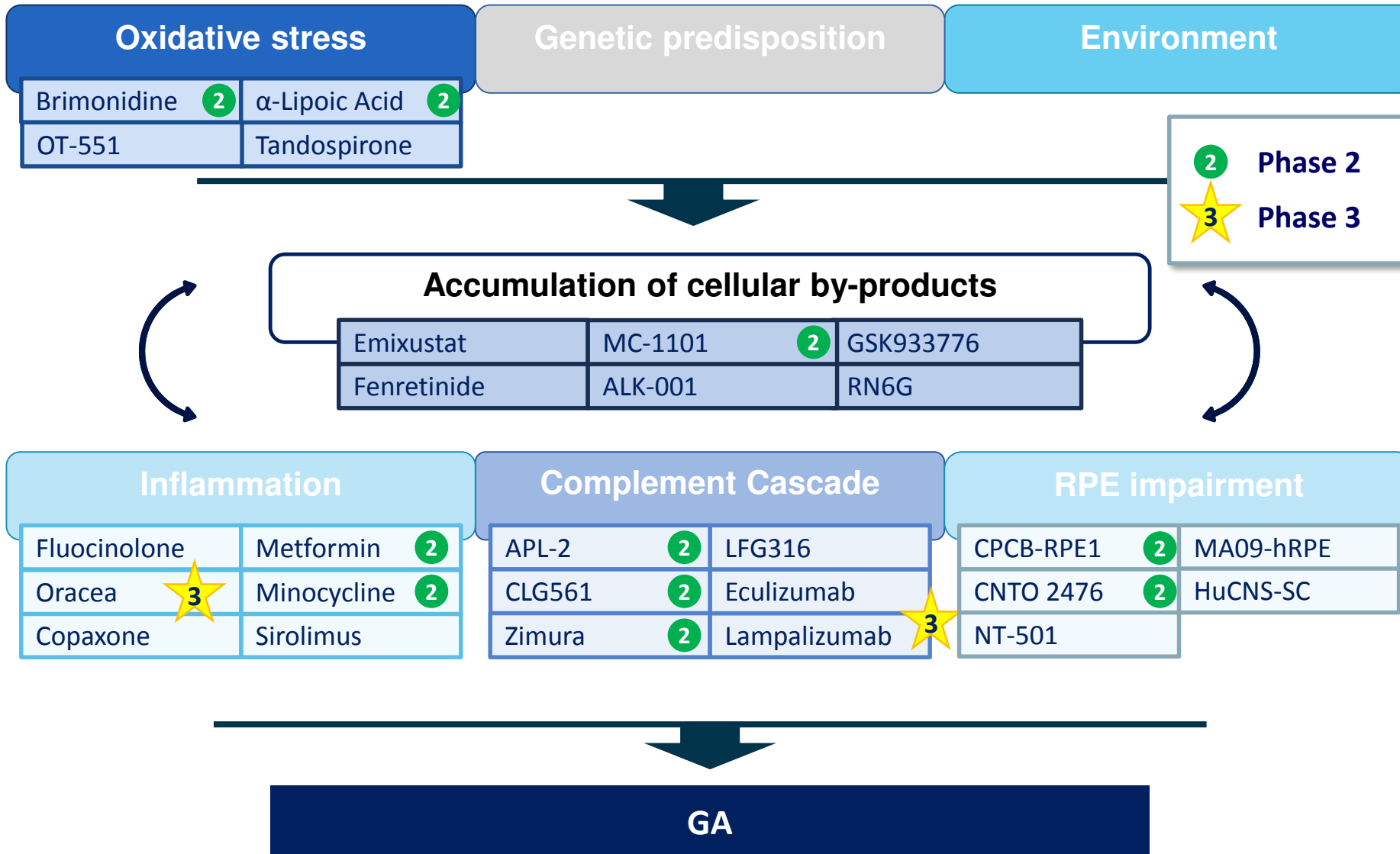
Mesopic vs. scotopic



Dark adaptation

Difficulties with night vision, delays in rod-mediated dark adaptation

Interventional GA trials



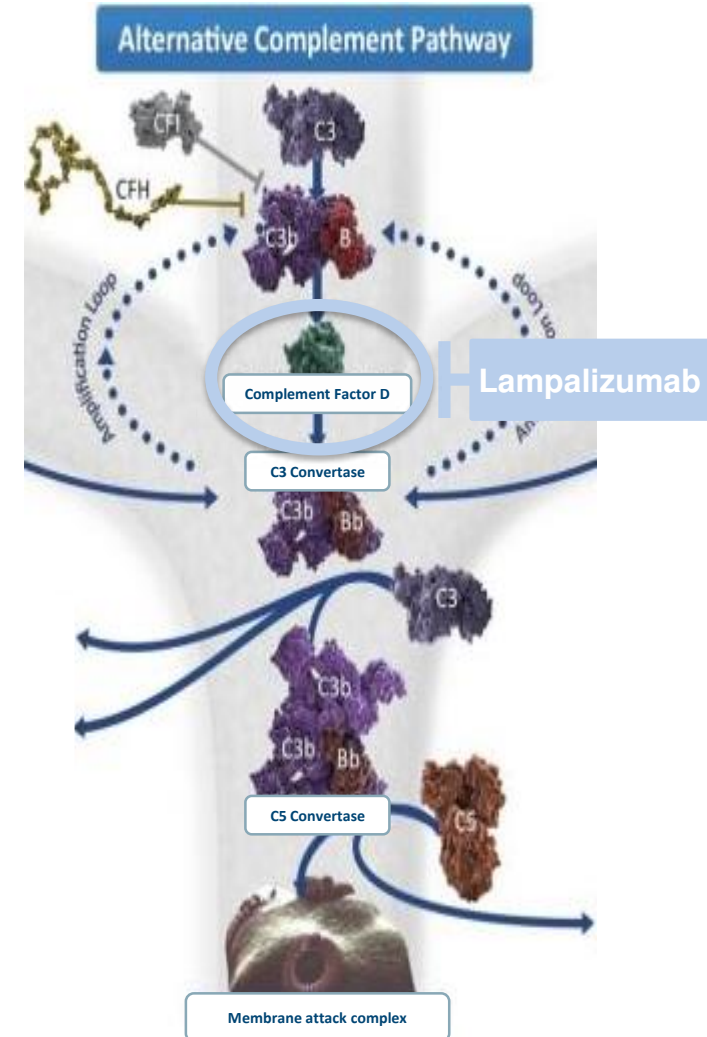
Lampalizumab: Selective Inhibitor of Complement Factor D, the Rate-limiting Enzyme of the Alternative Complement Pathway

Scientific rationale: genetic evidence implicates complement cascade dysregulation in GA/AMD^{1,2}

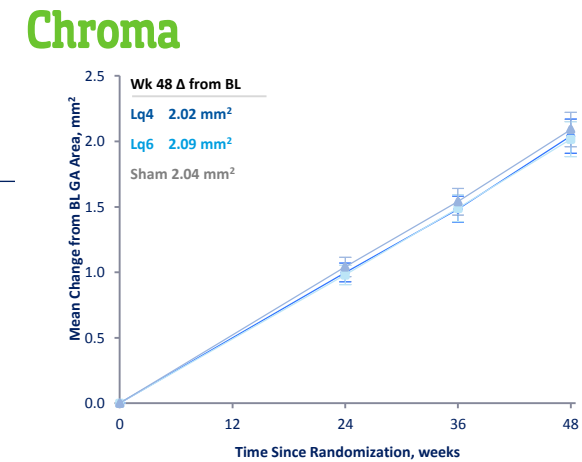
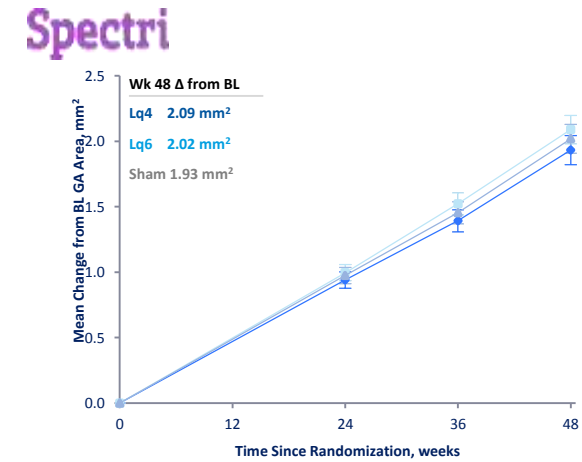
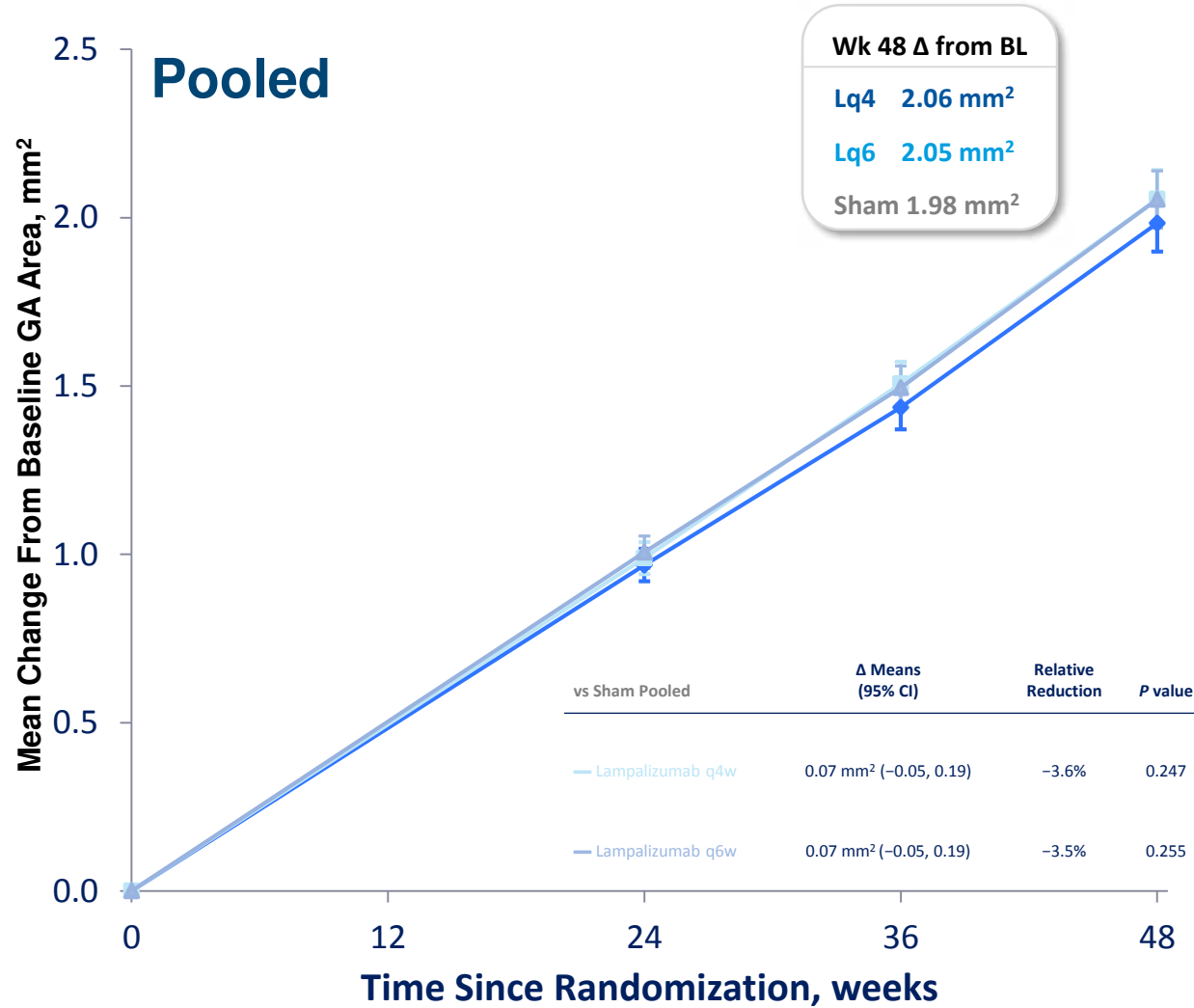
Complement factor D: rate-limiting enzyme of the alternative complement pathway with lowest plasma concentration of complement proteins^{3,4}

Lampalizumab: an antigen-binding fragment of a humanized monoclonal antibody that inhibits complement factor D^{3,4}

Phase 2 Mahalo: GA area progression from baseline to 18 months was reduced by 20% in the monthly lampalizumab-treated group versus sham⁵



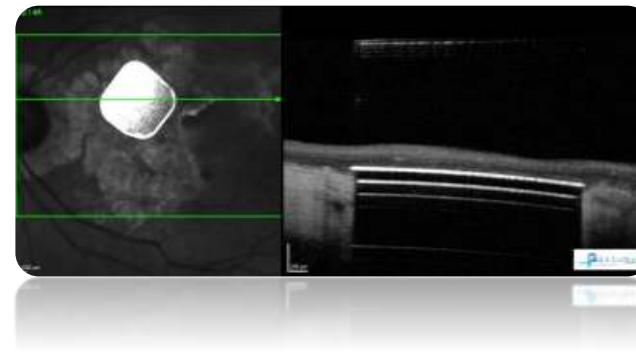
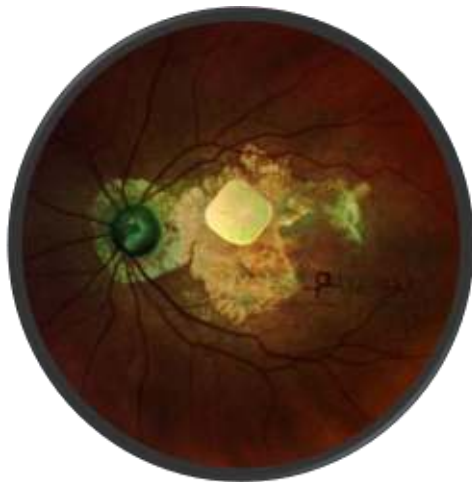
GA Area Growth From Baseline Over Time to Week 48

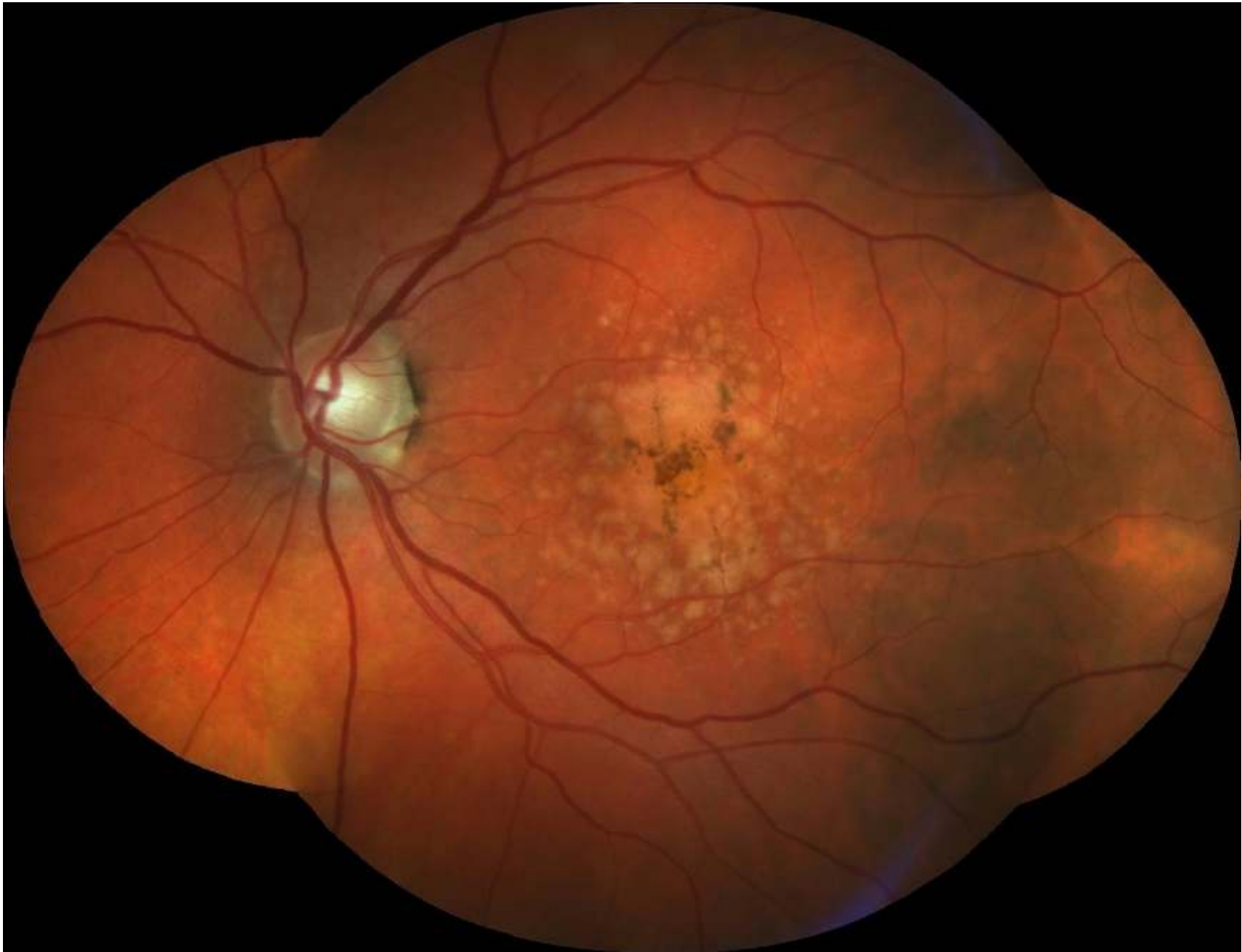

Age-related macular degeneration (AMD)

Dry AMD – how to proceed

- See how C3-inhibition works in phase 3
- Role of the ARMS2/HTRA1 risk polymorphism?
- Identify new targets
- Restoring function with device
- Define acceptable endpoints for earlier intervention



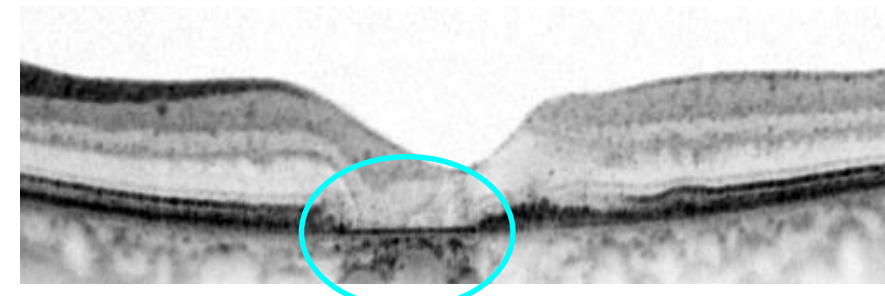
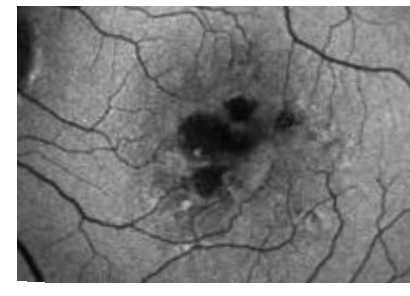
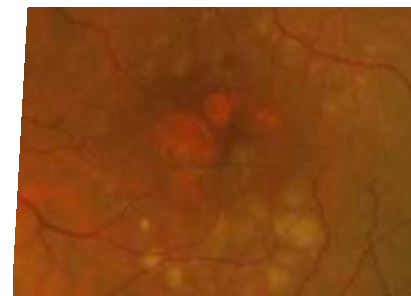
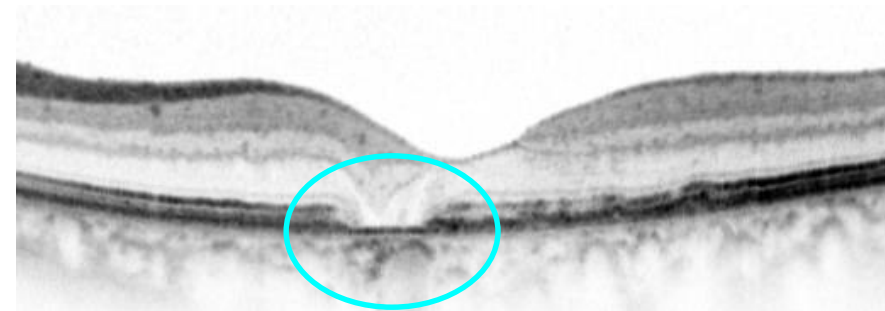
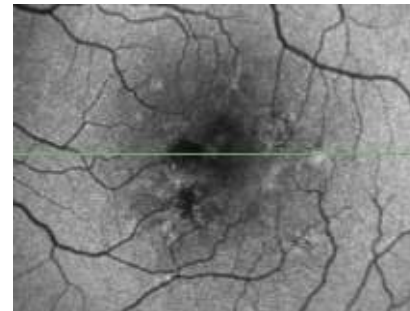
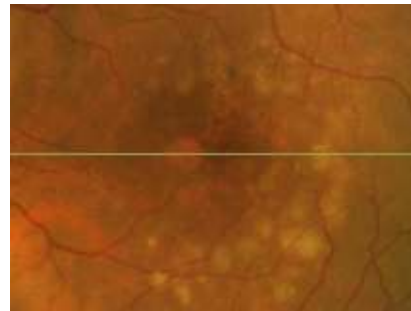
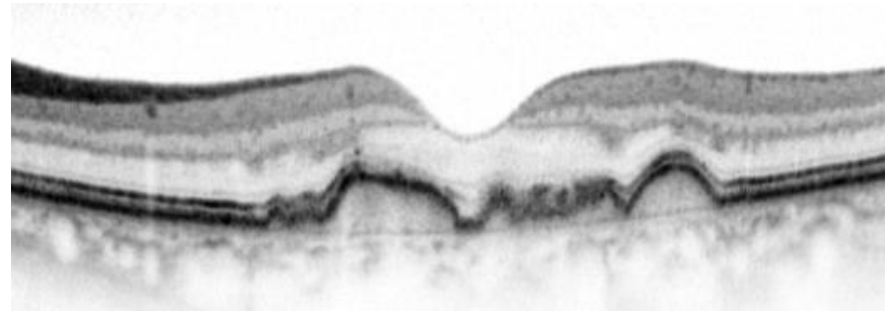
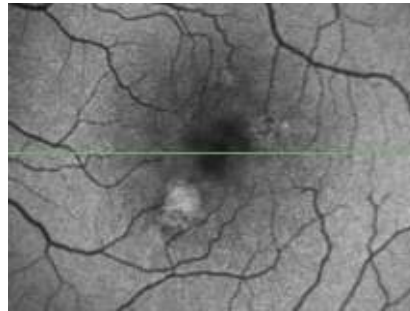
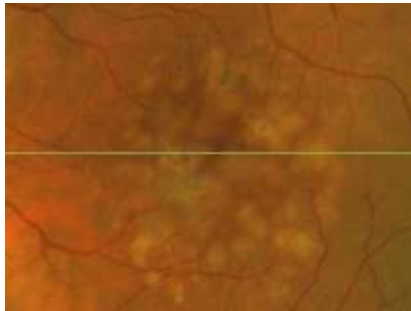


Earlier Intervention?

CFP

FAF

SD-OCT



MACUSTAR Clinical Sites across Europe

16 Mio €

United Kingdom:

- Moorfields Eye Hospital, London
- The Queen's University, Belfast
- Gloucestershire Hospitals, Cheltenham

The Netherlands:

- Radboud University Medical Center, Nijmegen
- Leiden University, Leiden

France:

- Institut de la Vision, Paris
- Centre Hospitalier, Creteil

Portugal:

- Association for Innovation and Biomedical Research on Light and Image (AIBILI), Coimbra
- Porto Medical School, Porto

Denmark:

- Rigshospitalet, Copenhagen

Germany:

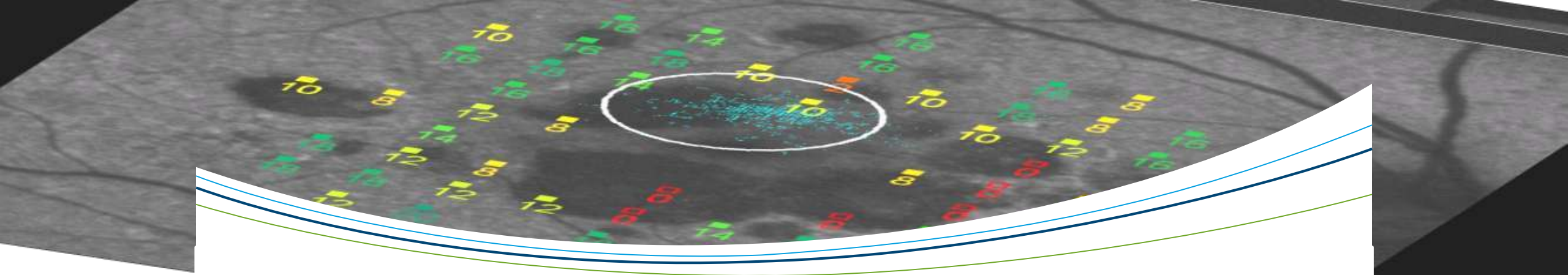
- University Eye Hospital Bonn
- University Eye Hospital Tübingen
- University Eye Hospital Munich
- University Eye Hospital Freiburg
- University Eye Hospital Cologne
- University Eye Hospital Ulm
- St. Franziskus Hospital Münster

Italy:

- G. B. Bietti Eye Foundation, Rome
- Luigi Sacco Hospital, Milan
- University Vita Salute, Milan

blue = consortium members (beneficiaries)

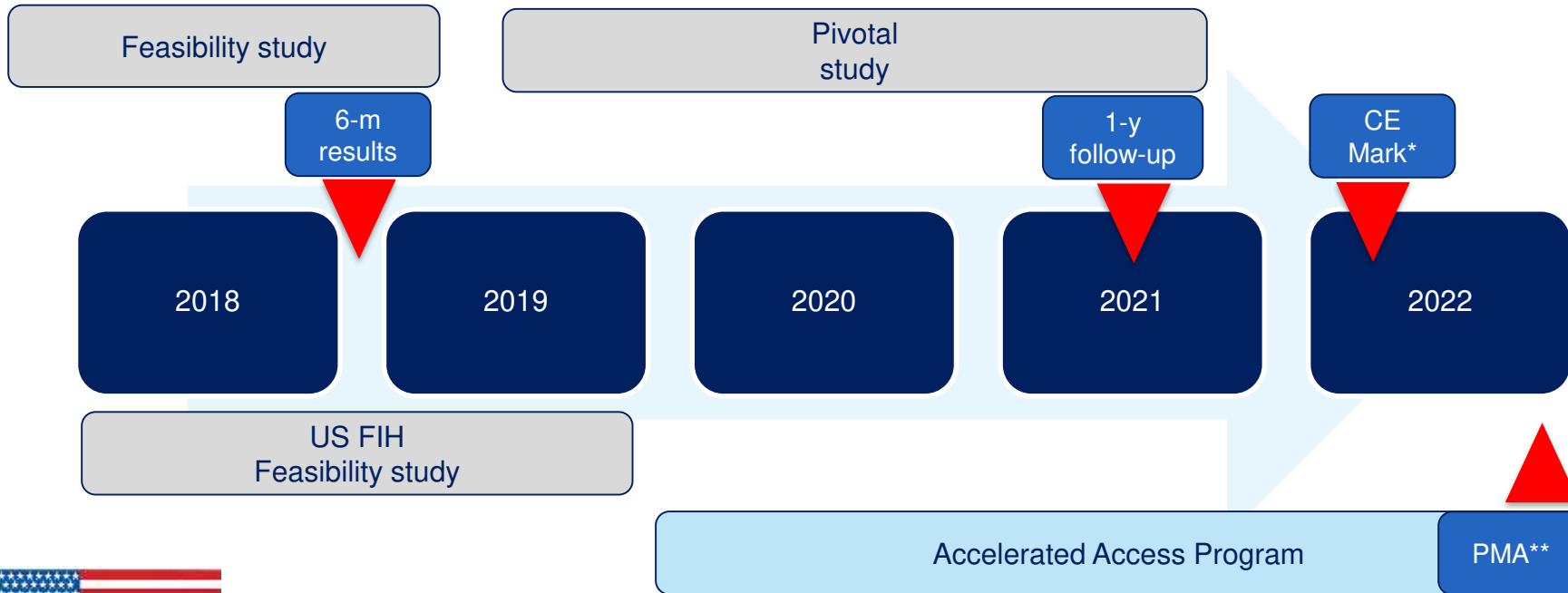
black = third parties providing in-kind against payment



Thank you



PRIMA device development plan in dry-AMD



*CE Mark – EU regulatory approval to commercialize
**PMA – US FDA regulatory approval to commercialize



CONVERTING **LIGHT**
INTO **VISION** AGAIN

KOL EVENT MEETING

An update on promising results with PRIMA in
advanced dry-AMD

MARCH 5, 2018

